

---

## TRANSMISSIBLE VENEREAL TUMOUR IN A DOG: A CASE REPORT

Jena D. <sup>\*1</sup>, Mishra P.K.K.<sup>1</sup>, Teja E. R. R.<sup>2</sup>, Kumar V.<sup>1</sup>, Sakshi <sup>3</sup> and Choudhary A. <sup>3</sup>

<sup>1,2</sup>Assistant Professor, <sup>3</sup>Internee

<sup>1</sup>Unit of Teaching Veterinary Clinical Complex, <sup>2</sup> Dept. of Veterinary Anatomy  
Faculty of Veterinary & Animal Sciences, Institute of Agricultural Sciences,  
Banaras Hindu University, Mirzapur, 231001

\*Corresponding author: krishna5dj@gmail.com

---

### ABSTRACT

A six years German shepherd dog was presented with history of sero-sanguinous discharge from penile region over a year. Upon physical and clinical examination and consequent to laboratory findings it was confirmed as transmissible venereal tumour. The animal was first stabilised and then treated with vincristine sulphate @ 0.025 mg/kg, Inj. IntacefTazo™ @ 20 mg/kg, Syp. Advaplate™ (2 tsf daily) and syp. Dexorange™ (2 tsf daily). The animal was treated for a period of 8 weeks and the tumour mass resorbed completely.

**Keywords:** TVT, canine

### INTRODUCTION

Canine transmissible venereal tumour (TVT) which is otherwise termed as Sticker's sarcoma, transmissible venereal sarcoma, infectious sarcoma, venereal granuloma or transmissible lymphosarcoma, is a contagious tumour

that predominantly occur in dogs. The gross nodular morphology of the tumour is pedunculated multilobular mass with cauliflower like contour. The tumour mass may range from small nodules to large in size with little metastatic nature. chromosome numbers of TVT cells are quite different from normal cells with 56-64 pairs in contrast to normal 78 (2n) in dogs.

One of the major etiological causes is transplantation of tumour cells from the affected area to the mucous membrane, particularly to membranes that have lost their integrity. Sexual intercourse is considered a major route of transmission. However, other social behaviors of dogs like licking and sniffing aid in the transmission of TVT. The lesions are most commonly located on the genital areas, but have also been observed in other locations, such as the skin, conjunctiva, oral and nasal cavities which are due to licking of affected areas.

## CASE HISTORY AND OBSERVATION

A German Shepherd male dog aged six years was presented to Palkapya Teaching Veterinary Clinical Complex, FVAS, B.H.U. with complaints of swelling around penile region and intermittent bleeding from the same area since last year. The appetite of the animal was normal and deworming and vaccination status was up-to-date.

Upon general examination all the vital parameters were normal and clinical examination, revealed cauliflower like growth around the penile tissue and profuse sero-sanguinous discharge upon examination of tumour mass. The nodular mass was fragile and some portion was detached during examination (Fig. 8).

Impression smear was taken from penile tissues and tissue was sent for histopathological analysis. The cytological analysis clearly showed the cytoplasmic vacuolation along with rounded singular cell typical of TVT cases (Fig 1). Moreover, histological analysis also revealed round to oval nuclei with vacuolation (Fig. 2).

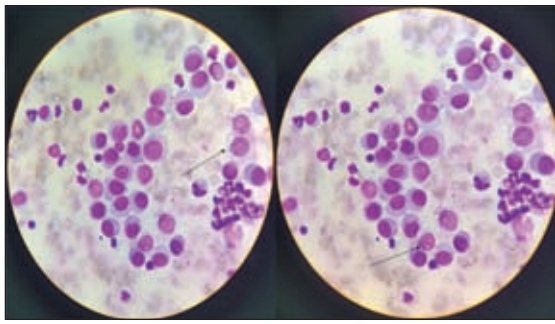
Blood sample was collected before institution of therapy and on alternate weeks during treatment for complete blood count, kidney function test (KFT) and liver function test (LFT). The complete haematological observations are given in fig 3 to 5 which showed non-significant changes throughout treatments except

platelet count and neutrophil count which came to normalcy at culmination of the treatment. The kidney function and liver parameters were in normal range throughout the treatment (Fig. 6 and Fig. 7).

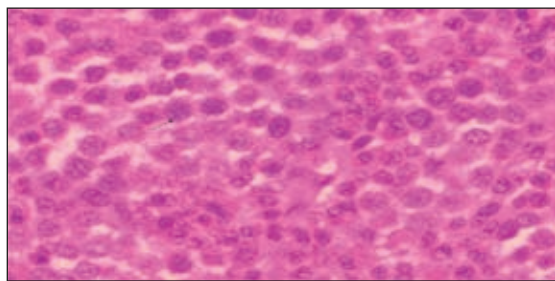
## TREATMENT AND DISCUSSIONS

Noting the fact that the animal had higher WBC count, the dog was first treated with Inj. ceftriaxone – tazobactam @ 25 mg/kg OD for 5 days and other supportive treatments like syrup Advaplate™ to cover up the platelet and Dexorange™ as hematinic syrup for 7 days. After 7 days of aforementioned treatment the animal was treated with Vincristine sulphate @ 0.025 mg /kg body weight with 100 ml of normal saline by slow intravenous route at weekly interval. After eight weeks of the treatment the mass regressed completely with stoppage of bleeding.

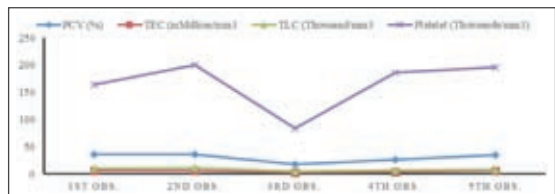
Transmissible venereal tumour is one of the most commonly occurring round cell tumours which generally transmit sexually (Thangathurai *et al.*, 2008). Confirmatory diagnosis can be made from the peculiar morphology, cytological and histopathological characteristics. In this case report the tumour mass was diagnosed as TVT based on the location of the tumour mass, cytological analysis and histopathological observations. The prominent cytological feature of TVT is the presence of cytoplasmic vacuolation. The size and number of individual punctate



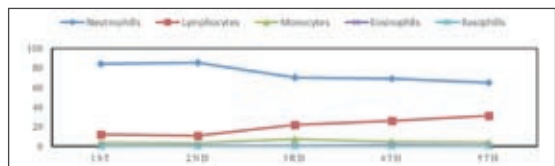
**Fig 1:** TVT cytology. Homogenous and round sheet like tumour cells with cytoplasmic vacuolation (100×).



**Fig 2:** Photomicrograph showing tumour tissue from the penis of the dog. H&E x40. Black colour arrows showing oval nuclei of large round cells

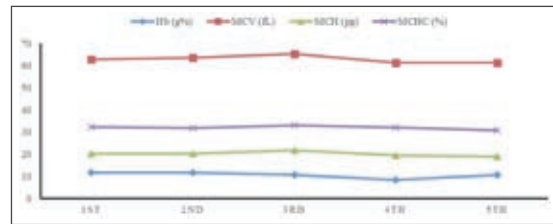


**Fig 3:** Haematological analysis of the TVT treated animal taken during different observations.

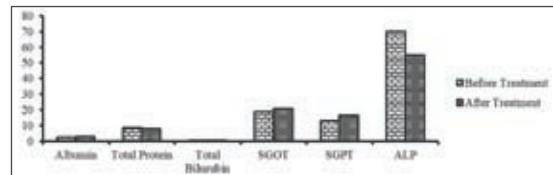


**Fig 4:** Differential count of the TVT treated animal at different point of observation


vacuoles vary with tumour cell morphology (Thangathurai *et al.*, 2008). Large number of TVT cells per field with cytoplasmic vacuolation was observed (Fig. 1). Moreover, the presence of round individual cells in an arborizing fibrovascular network



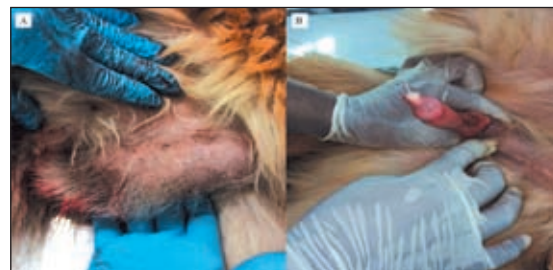**Fig 5:** Mean corpuscular volume (MCV), Mean corpuscular haemoglobin (MCH) and Mean corpuscular haemoglobin concentration (MCHC) analysis of the TVT treated animal at different time point.



**Fig 6:** Liver function tests comprising Albumin, Total protein, Serum Glutamic Oxaloacetic Transaminase (SGOT), serum glutamic pyruvic transaminase (SGPT) and Alkaline phosphatase (ALP) test sampled at beginning and end of the treatment



**Fig 7:** Kidney function test involving Blood urea, Blood nitrogen and serum creatinine at the beginning and end of the treatment.



**Fig 8:** TVT affected penis before and after treatment (A-before treatment, B-after treatment).

could help in diagnosing the tumour histologically (Fig 2). These observations concurred with those of earlier studies (Krithiga *et al.*, 2005).

Treatment of TVT includes complete surgical excision, radiation therapy and

chemotherapy; although immunotherapy has not been proven effective. In surgical correction there is low rate of efficacy due to tumour cell transplanted into the surgical wound during operation. TVT has been proven to be highly sensitive to irradiation, with dosage recommendations range from 1500 to 2500 rads, divided in sessions of 400-500 rads over a period of 1-2 weeks, or a single dose of 1000 rads which, if not curative, can safely be repeated 1-4 times. However, radiotherapy lacks practicality due to constraints also (Boscos and Ververidis, 2004). Taking these factors into consideration, chemotherapy is considered the treatment of choice and most common chemotherapeutic agent used is Vincristine sulphate. Although it is commonly practised to give through intravenous route, few studies are there where vincristine had been given intratumorally with higher dose. The tumour mass was completely resorbed following 8 weeks of treatment. However, a very small fraction of remnant tissue was visible at the end treatment which was not bleeding upon application of pressure. The same had been opined by Boscos and Ververidis (2004). At the end of the treatment there was no side effects like hair loss, haematological disorders or kidney and liver function anomaly as observed through laboratory analysis.

## SUMMARY

A case of TVT, diagnosed by impression smear cytology and histopathology along with morphological characteristics, was treated successfully with Vincristine sulphate and other supportive therapy. At the culmination of treatment, the blood parameters along with KFT and LFT functions were found to be normal.

## REFERENCES

- Boscos, C.M. and Ververidis, H.N. 2004. Canine TVT: Clinical findings, diagnosis and treatment. Scientific proceedings WVA-FECAVAHVMS World Congress 2: 758-761.
- Krithiga, K., Manohar, B. M. and Balachandran C. 2005. Cytological and histopathological study on cutaneous round cell tumours in canines. *Indian J. Vet. Pathol.* **29**: 38-41.
- Thangathurai, R., Balasubramaniam, G. A., Dharmaceelan, S., Periasamy, B., Palaniyappan, S., Soundarapandian, S. and Bhakthavasalam, M. M. 2008. Cytological diagnosis and its histological correlation in canine transmissible venereal tumour. *Vet. Archiv.* **78** (5): 369-376.

