

ECHOCARDIOGRAPHIC EVALUATION OF PERICARDITIS IN AN ELEVEN MONTH OLD HEIFER CALF - A CASE REPORT

K. Mohanambal, R. Ravi, G. Vijayakumar*, S. Sivaraman and B. Sudakara Reddy

Department of Veterinary Clinical Medicine, Veterinary College and Research Institute, Namakkal, Tamil Nadu - 637 002

*Corresponding author: drvijaymvc@gmail.com

Received: 09-04-2018 Accepted: 24-04-2018

ABSTRACT

An eleven month old Jersey cross bred heifer calf was presented to Veterinary College and Research Institute, Namakkal with the history of anorexia and voiding pellety dung. Clinical examination revealed dullness, jugular vein engorgement and muffled heart sound. Echocardiographic examination showed anechoic pericardial fluid and echogenic fibrin in the pericardial cavity.

Keywords: Heifer calf, jugular vein engorgement, pellety dung, echocardiography

INTRODUCTION

Pericarditis is an inflammation of the pericardium with accumulation of serous or fibrinous inflammatory exudates. Reticular foreign body is one of the etiological factors for the pericarditis in cattle, leading to tachycardia, muffled heart sounds, distension of the jugular veins, submandibular, brisket and ventral abdominal oedema (Braun, 2009).

CASE HISTORY AND OBSERVATION

An eleven month old Jersey cross bred heifer calf weighing about 110 kg was presented to Veterinary College and

Research Institute, Namakkal with the history of anorexia and voiding pellety dung for a period of 10 days. Clinical examination revealed dullness, jugular vein engorgement with positive venous stasis (Fig.1) and muffled heart sounds.

Haematobiochemical examination revealed leukocytosis (13,000/ μ L) and elevated AST (85IU/L). Echocardiography revealed the presence of anechoic fluid surrounding the heart with echogenic fibrin in between the pericardial layers suggestive of pericarditis (Fig. 2).



Fig.1. Jugular vein engorgement with positive venous stasis

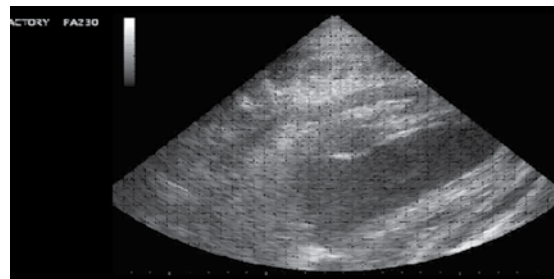


Fig.2. Anechoic fluid with echogenic fibrin in between the pericardial layers

TREATMENT AND DISCUSSIONS

The heifer calf was treated with inj. streptopenicillin (10 mg/ kg, IM), flunixin meglumin (1.1 mg/ kg, IM) and frusemide (2 mg/ kg, IM) for five days. A definitive diagnosis of traumatic pericarditis was made by characteristic clinical signs (Radostits *et al.*, 2000) viz., distension of both jugular veins, muffled heart sounds and echocardiographic features like anechoic fluid filled space surrounding the heart and strands of fibrin in the pericardium (Braun, 2009). Traumatic pericarditis in cattle usually occurs following calving or in last month of pregnancy. In the present case, traumatic pericarditis is reported in non-pregnant heifer calf.

SUMMARY

Echocardiographic evaluation of traumatic pericarditis in an eleven month old Jersey cross bred heifer calf was reported.

REFERENCES

- Braun, U. 2009. Traumatic pericarditis in cattle: Clinical, radiographic and ultrasonographic findings. *Vet. J.* **182**(2): 176-186.
- Radostits, O.M., Gay, C.C., Blood, D.C. and Hinchliff, K.W. 2000. Diseases of the cardiovascular system. In: *Veterinary Medicine: A Text book of the Diseases of Cattle, Sheep, Pigs, Goats and Horses*. 9th ed. London, Saunders. pp. 361-398.

