

SURGICAL REPAIR OF UNILATERAL PERINEAL HERNIA WITH HYPERPLASTIC PROSTATE IN AN INTACT MALE DOG

Amitha Banu S.^{*1}, Manjusha K. M.¹, Khan Sharun¹ and A. M. Pawde²

¹PhD scholar, ²Principal Scientist, Division of Surgery,
ICAR-Indian Veterinary Research Institute, Izatnagar, Bareilly, Uttar Pradesh, India

*Corresponding author: aamianchu@gmail.com

ABSTRACT

Perineal hernia is a frequently encountered condition in dogs, especially in middle and old-aged intact dogs. A nine-year-old Labrador retriever was presented to Referral Veterinary Polyclinic, ICAR-IVRI, with a history of swelling in the perineal region since last four months. The history, clinical examination and radiographic findings suggest perineal hernia (PH). The confirmative diagnosis of PH was made surgically and the hernial contents were identified as hyperplastic prostate and urinary bladder. Post-operatively animal was maintained using antibiotics, analgesics, and supportive treatment. Animal was strictly maintained in liquid and semi-solid diets for the subsequent days and made an uneventful recovery.

Keywords: Perineal herniorrhaphy, Canine, Prostate, Urinary bladder.

INTRODUCTION

Perineal hernia (PH) is the herniation of pelvic and occasionally, other abdominal organs into the subcutaneous perineal region (Heishima *et al.*, 2022). Rectum passes through a vertical enclosure in the pelvic cavity, termed as pelvic diaphragm. Pelvic diaphragm is bordered laterally by levator ani, coccygeous muscle and sacrotuberous ligament, ventrally by internal obturator and superficial gluteus, and medially by external anal sphincter (Sjollem & van Sluijs, 1989). The underlying cause of PH is identified as the weakening of the pelvic diaphragm through which the contents protrude out (Kitessa and Terefe, 2022). The predisposing factor includes hormonal imbalance, prostatic hyperplasia, docking and chronic constipation that invariably leads to degenerative change in the pelvic musculature (Sprada *et al.*, 2017).

PH is commonly reported in

middle-aged or older intact male dogs. It is usually presented as unilateral or bilateral, non-painful swelling in the perineum. The clinical signs vary from absence of any signs to constipation, obstipation, tenesmus, rectal prolapse, etc (Gill and Barstad, 2018). The commonly reported contents of PH are fat, serous fluids, urinary bladder, intestinal loops, prostate, uterus (in females), etc. The confirmative diagnosis is made from the history, clinical signs, radiograph and ultrasonography. Surgical repair is necessary for the correction of perineal hernia as it involves the weakening of perineal musculature. The techniques for correction involve primary herniorrhaphy, muscle flap transposition technique, natural or synthetic implant techniques, and laparotomy with colopexy and cystopexy (Kann, 2010). The present case report discusses in brief about the surgical repair of perineal hernia with hyperplastic prostate in an intact male dog.

CASE HISTORY AND OBSERVATION

Animal exhibited alternating episodes of constipation and diarrhoea in the past four weeks along with stranguria. On clinical examination, physiological parameters were within the normal range and animal showed bulged mass on the left side of the anus (Fig 1a). The mass was observed to be reducible to the pelvic cavity through a palpable defect of the

pelvis musculature. A lateral abdominal radiograph revealed soft tissue opacity in the protruded mass and absence of bladder and prostate shadow in the caudal abdomen (Fig 1b). After preoperative preparations and pre anaesthetising with diazepam at the rate of 0.5 mg/kg IV, anaesthesia was induced using ketamine hydrochloride at the rate of 5 mg/kg body weight IV. Anaesthesia was maintained using 2% isoflurane till effect.

The dog was positioned in ventral recumbency with tail pulled over the back. The surgical site was prepared aseptically. The pelvis was kept in elevated position and anal opening was temporarily closed using a purse string suture. A 6-8 cm long curvilinear skin incision was placed over the herniated mass. The subcutaneous and supportive tissues were dissected and the hernial sac was incised. The contents were identified as enlarged hyperplastic prostate along with urinary bladder (Fig 2a). Herniorrhaphy was performed after reducing the contents back to the pelvic cavity. The pelvic diaphragm was repaired using polyglactin 2-0 in an interrupted manner along with transposition of gluteal muscles over the defect. Skin and subcutis were apposed in routine manner (Fig 2b).

Animal was post operatively managed with intravenous fluids and antibiotics. Ceftriaxone was given at the

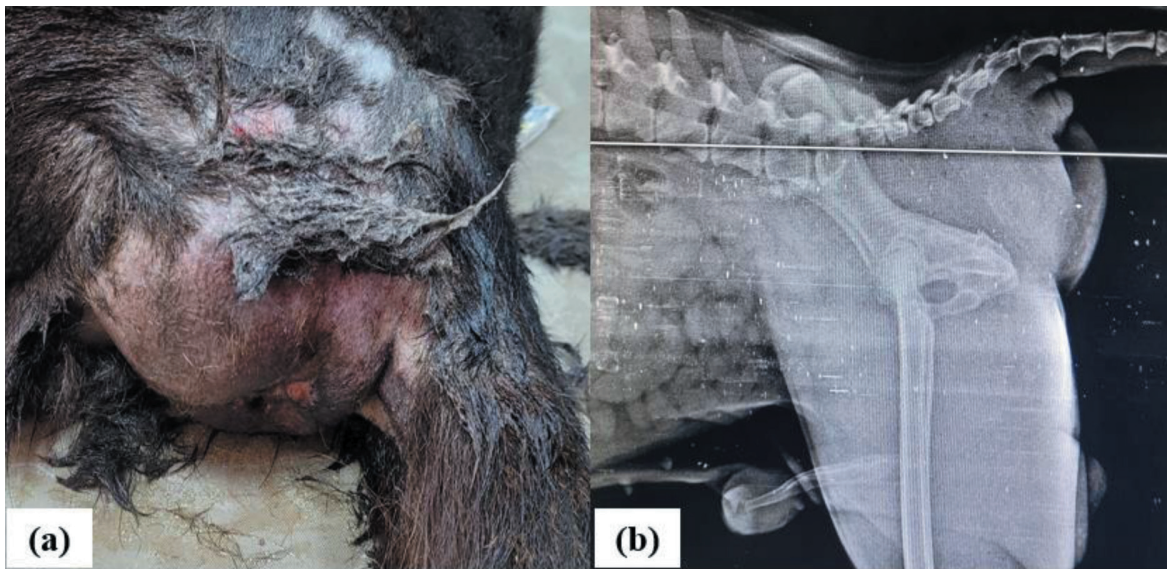


Fig 1: (a) Protruded mass on the left side of the anus. (b) Lateral abdominal radiograph revealed soft tissue opacity in the protruded mass and absence of bladder and prostate shadow in the caudal abdomen

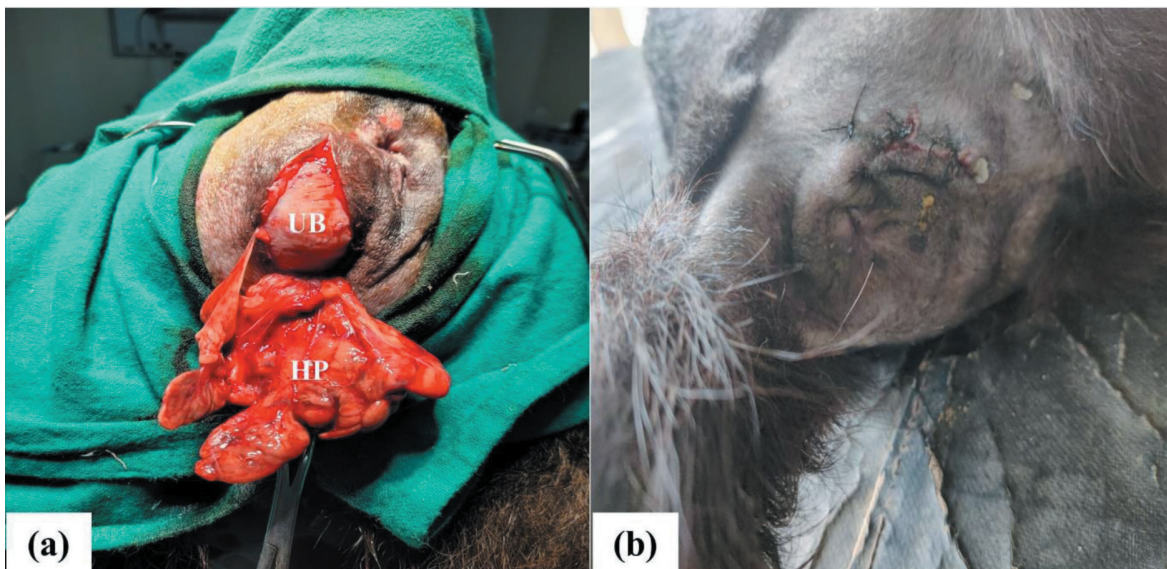

Fig 2: (a) The hernial contents were identified as enlarged or hyperplastic prostate (HP) along with urinary bladder (UB). (b) The skin and subcutis were apposed in a routine manner.

rate of 20 mg/kg body weight for seven days IV and meloxicam at the rate of 0.2 mg/kg body weight for five days was given intravenously. Low dose finasteride at the rate of 0.1 mg/kg was given orally for one

month. Animal was strictly maintained in a liquid diet for the first week and a semisolid diet for the following three weeks. Sutures were removed on the 10th post operative day. Open-open castration was also

performed after one month of finasteride therapy to reduce the chance of recurrence. The animal made an uneventful recovery.

TREATMENT AND DISCUSSIONS

PH is herniation of the pelvic content into the subcutaneous tissue through a defective pelvic musculature. Reports suggests that 25-59% of the presented cases exhibited concurrent affection of prostate (Zambelli *et al.*, 2022). Surgical repair is the gold standard treatment for the correction of PH. Reduction of PH is conveniently achieved only if the size of herniated organs are reduced, especially the prostate. The hyperplastic prostate can be well managed using finasteride treatment given for 2-3 months. Castration is always recommended for management of both hyperplastic prostate and perineal hernia (Kim, 2022).

In the present case, animal was intact as well as aged that might have predisposed to hyperplasia of the prostate. The enlarged prostate might have invariably altered the testosterone levels and thereby contributed to perineal hernia. In this case, we did not conduct preoperative ultrasound imaging of the lower abdomen or the contents of the hernia. The mass was reducible and there was absence of adhesion of the hernial contents, which reduced surgical complications.

CONCLUSION

PH is a commonly presented clinical condition in small animal practice. The underlying cause should be removed for a successful outcome. The timely and prompt management of the present case along with proper post-operative care contributed to the successful recovery of the animal.

ACKNOWLEDGEMENT

The authors thank the Head, RVP-TVCC, Izatnagar, for providing the facility to conduct various examinations.

REFERENCES

- Gill, S. S., and Barstad, R. D. 2018. A review of the surgical management of perineal hernias in dogs. *J. Am. Anim. Hosp. Assoc.* **54**(4), 179-187.
- Heishima, T., Asano, K., Ishigaki, K., Yoshida, O., Sakurai, N., Terai, K., and Tanaka, S. 2022. Perineal herniorrhaphy with pedunculated tunica vaginalis communis in dogs: Description of the technique and clinical case series. *Front. Vet. Sci.* **9**, 931088.
- Kann, B. R. 2010. Perineal hernias. *J. Long-Term Eff. Med. Implants.* **20**(2), 149-157.
- Kim, H. 2022. Finasteride therapy in a dog with benign prostatic hyperplasia. *J.*

- Anim. Sci. Biotechnol.* **37**(3), 209-212.
- Kitessa, J. D., and Terefe, K. B. 2022. Perineal herniorrhaphy along with anal saccullectomy in dog: Case report. *Int. J. Vet. Sci. Res.* **8**(2), 039-042.
- Sjollema, B. E., and van Sluijs, F.J. 1989. Perineal hernia repair in the dog by transposition of the internal obturator muscle. II. Complications and results in 100 patients. *Vet. Q.* **11**(1):18-23.
- Sprada, A. G., Huppes, R. R., Feranti, J. P. S., de Souza, F. W., de Paula Coelho, L., Moraes, P. C., and Minto, B. W. 2017. Perineal hernia in dogs: which technique should we use. *Acta Sci. Vet.* **45**, 7-7.
- Zambelli, D., Ballotta, G., Valentini, S., and Cunto, M. 2022. Total Perineal Prostatectomy: A Retrospective Study in Six Dogs. *Animals.* **12**(2), 200.