

---

## A COMPILATION OF FOUR CASES OF SUCCESSFUL SURGICAL MANAGEMENT OF FOREIGN BODY OBSTRUCTION IN CANINE

Anoop R<sup>1\*</sup> and Rekha A<sup>2</sup>

<sup>1</sup>Veterinary Surgeon, Multispeciality Veterinary Hospital, Kudappanakunnu, Trivandrum, Kerala- 695043

<sup>2</sup>Food Safety Officer, Chathannoor circle, Mini Civil Station, Kollam, Kerala-691572

\*Corresponding author: [anoopvet@gmail.com](mailto:anoopvet@gmail.com)

---

### ABSTRACT

Dogs are curious by nature; they love to investigate new sights, smells and tastes. Unfortunately this usually leads them in to trouble, by causing foreign body ingestion and subsequent complications like alimentary tract obstruction and perforation. 'Pica' is another important reason for foreign body ingestion, especially in puppies. A gastric/enteric foreign body is anything that is ingested by an animal that cannot be digested, which eventually may cause obstruction. This is an evaluative report of four different cases of foreign body ingestion in dogs and its successful surgical management. Four canine patients belonging to different age groups, diagnosed (through radiography) with foreign body ingestion were subjected to laparotomy (gastrotomy/enterotomy) under general anaesthesia. A fish hook, an open safety pin, an aquarium pebble and a metal vessel lid were the objects recovered from these patients individually. Irrespective of recovery site, all patients

exhibited acute vomiting as a common symptom. With timely and precise diagnosis, surgical intervention and post-operative management, all patients showed a complete, uneventful recovery post-surgery. This report notes that ingested foreign bodies (especially penetrating type) in dogs should always be considered as an emergency and can be surgically managed in field with great success rate.

**Keywords:** Dogs, Foreign body, Laparotomy, Vomiting, Emergency.

### INTRODUCTION

Dogs were the first domesticated wild animal as companions for the ever evolving humans. Gastro intestinal obstruction can result from neoplasia, foreign bodies, polyps, gastric dilatation, volvulus, gastric hypertrophy, intussusceptions and incarcerations (Atray *et al*, 2012). Surgical interventions related to the treatment of small intestinal obstruction represents approximately 0.5-1 percent of all surgical procedures in dogs

(Crha *et al*, 2008). Pica and curiosity are the main reasons for foreign body ingestion and subsequent complications like gastric/intestinal obstruction. The present report is regarding four different cases of foreign body ingestion in dogs belonging to different age groups. This report also showcases the clinical signs, diagnostic imaging and successful surgical management of all the four cases.

**CASE HISTORY AND OBSERVATION**

The patients under this report belonged to different age groups, viz. 5years Pomeranian female (Patient I), 3years Pomeranian female (Patient II), 2 years Labrador male (Patient III) and 6 months Pomeranian female (Patient IV). All the patients were presented with proper vaccination history and deworming. All the four patients were screened negative for microfilaria and other haemoprotozoans. Owners of all the patients gave a hint that their dogs showed pica as a behavioural

problem. Irrespective of the age, sex, breed and the site of recovery of the foreign body, all the four patients showed severe acute vomiting as a common symptom. Patient I, which had ingested the aquarium pebble was showing 4 days of anorexia and had not defecated for last 4 days and also revealed a hard abdominal mass on palpation, which was showing hyper-echogenicity on ultrasound scanning. All the patients were having a normal renal and liver function test values. The symptoms and observations regarding the 4 cases are summarized in Table: 01. The patients were subjected to radiography, except Patient IV with ingested fish hook because the owner was well confident about the ingested material and moreover the twine of the fish hook was hanging out of the mouth of the patient. From the radiographs, the site of ingested foreign body was realized (Photos: 01 to 03). With the radiographs as the prime evidence, all the patients were subjected to laparotomy.

Table: 01

Symptoms and Observations	Patient I, with ingested <b>aquarium pebble</b>	Patient II with an ingested <b>open pin</b>	Patient III with a <b>metal vessel lid</b>	Patient IV, which had an ingested <b>fish hook</b>
Temperature	Increased	Increased	Increased	Normal
Mucous Membrane	Congested	Congested	Congested	Pale Rosette
Hemoglobin	Reduced	Normal	Normal	Normal
RBC Count	Reduced	Normal	Normal	Normal
Total WBC	Increased	Normal	Normal	Normal
Abdominal palpation	Hard mass over the lower abdomen	No mass on palpation	No mass on palpation	No mass on palpation

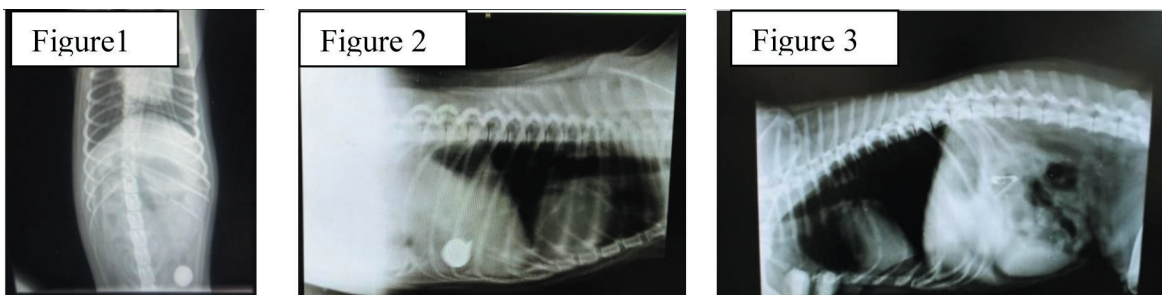


Figure 01: Radiograph of 5 year old female Pomeranian dog, with ingested aquarium pebble

Figure 02: Radiograph of 2 years old Labrador male dog with a metal vessel lid

Figure 03: The 3years old Pomeranian female dog with an open pin

### TREATMENT AND DISCUSSION

All the patients were subjected to laparotomy. Irrespective of the site of the foreign body in the radiograph, a midventral site was chosen. All the patients were pre-surgically stabilized with fluid therapy to avoid hypovolemic shock. The patients were prepared for the surgery by cleanly shaving the surgical site with antiseptic soap solution. Primary scrubbing of the surgical site was done with povidone iodine solution. Patients were pre-anaesthetised with atropine and dexamethasone injections. Induction of anaesthesia was done with ketamine and midazolam. After induction the patient was transferred to operation theatre. Secondary and final scrubbing of the surgical site was done with chlorhexidine solution. The surgical site was aseptically draped with sterile adhesive surgical drapes. Pre-surgical antibiotic, analgesic and haemo-coagulase injections were given intravenously. During the surgery, fluids and plasma volume expanders were given

intravenously. A 5 to 6cm long mid-ventral incision was placed from the umbilicus towards the xiphoid with surgical BP blade. The underlying fascia was dissected and a sharp single incision was placed on the linea-alba to reveal the underlying peritoneum, which was incised to reach the peritoneal cavity. In all the cases the GI tract was carefully screened starting from the stomach, small intestine and then large intestine without disturbing other organs. Luckily in all these 4 cases the foreign body could be palpated before putting an incision on the tract. The fish hook, open safety pin and the metal vessel lid were discovered from the stomach, while the aquarium pebble was found obstructing the ileo-caecal junction. The foreign bodies from the stomach were removed with an incision on the greater curvature of the stomach, while the intestinal foreign body was removed by placing an incision over the intestine, over the foreign body. Post removal of the foreign body, the incision was thoroughly washed with normal saline.

The incision on the stomach was closed with reverse cutting polyglactin {PGA} (3-0) suture in double simple continuous suture pattern and in intestine the closure was done with reverse cutting PGA (4-0) suture in double simple continuous suture pattern. The muscle layer and the subcuticular layers were closed under routine fashion with reverse cutting PGA (2-0) suture in simple continuous suture pattern. The skin was finally closed with reverse cutting nylon (3-0) suture in horizontal mattress. Anti-septic dressing was given over the surgical incision. Post operatively the patients were given antibiotics, analgesics, antihistamines, antacids, B-complex and fluid therapy for 6 days. Food was withheld for all the patients for first 5 days and water for first 2 days. All the patients were reviewed on the 8<sup>th</sup> post surgery day and showed no complications. The skin stitches were removed on the 15<sup>th</sup> day post-surgery. All the patients showed an uneventful and complete recovery.

From the anamnesis it was clear that the primary reason for the ingestion of the foreign bodies in all the 4 case was

pica. Pica is usually associated with several deficiencies, especially in case of puppies. This deficiency symptom later develop in to a behavioural disorder, in which the dogs keep on ingesting innate objects even though they might not have an apparent deficiency. The vomiting observed in all the cases may be due to the gastric irritation caused by the foreign body. The increased rectal temperature, congested mucous membrane and increased total WBC count may be attributed to the onset of infection and toxemia. Patient A, which had ingested the aquarium pebble showed a reduced hemoglobin and RBC count because of four days of complete anorexia and its absence of defecation may be due to the complete obstruction of GI tract. Plain radiography is the suitable method for diagnosis of metallic foreign body (Uma Rani *et al.* 2010). Symptomology of intestinal obstruction is usually nonspecific which include vomitions (which do not respond to antiemetic), anorexia, dehydration and loss of condition (Capak *et al.* 2001). Along with the clinical signs, abdominal palpation helps in making a presumptive diagnosis in gut obstruction (Peppler *et al.* 2008).

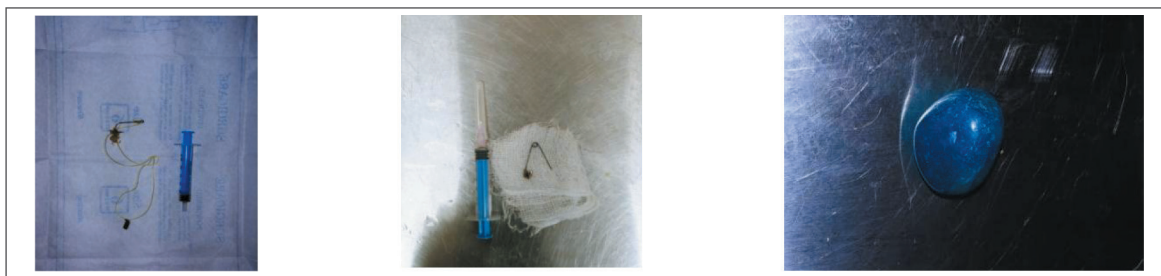

Figure 04 Recovered foreign bodies

## SUMMARY

Foreign bodies in stomach, if they lodge in the pyloric portion of the stomach, gastric emptying may be impaired (Uma Rani *et al.* 2010) leading to complications. Foreign bodies obstructing the intestine can cause fatal complications like intestinal rupture, intussusceptions etc. Gastrotomy is most often indicated for treatment of stomach problems including removal of foreign objects (Haragopal and Suresh Kumar, 1996) and has a favorable prognosis (Sluys 1993, Horstman *et al.* 2003). We recommend that ingested foreign bodies (especially penetrating type) in dogs should always be considered as an emergency presentation and with timely and precise diagnosis, surgical intervention and post-operative management, these type of cases can be surgically managed in field with great success.

## Acknowledgement:

We would like to express our gratitude to Department of Animal Husbandry, Kerala State. Deputy Director, Multi-Speciality Veterinary Hospital (MSVH), Kudappanakunnu, Dr Harikrishnakumar G. Doctors and all the supporting staff of this esteemed institute deserve our acknowledgement. Our special thanks to Dr Rajeev T, Senior Veterinary Surgeon, MSVH, without whom the

diagnosis of the cases presented would have been laborious. Special thanks to Dr Roshni G, for her unconditional help during the surgical procedures. We thank all the owners of our patients for their complete faith in us and their whole hearted support during the treatment.

## REFERENCES

- Atray, M., Raghunath, M., Singh, T. and Saini, N.S. 2012. Ultrasonographic diagnosis and surgical management of double intestinal intussusception in three dogs. *Canad. Vet. J.*, **53**(8): 860.
- Capak, D., Brrick, A., Harapin, I., Mticiv, D. and Radisic, B. 2001. Treatment of the foreign body induced occlusive ileus in dogs. *Vet. Archive.* **71**: 345-59.
- Crha, M., Lorenzova, J., Urbanova, L., Fitchel, T. and Necas, A. 2008. Effect of preoperative mortality in dogs with small bowel obstruction. *Acta Veterinaria Brno.* **77**: 257-261.
- Haragopal, V. and Suresh Kumar, R.V. 1996. Surgical removal of a fish bone from the canine esophagus through gastrotomy. *Can. Vet. J.* **37**: 156.
- Horstman, C.L., Eubig, P.A., Cornell, K.K., Khan, S.A. and Selcer, B.A. 2003. Gastric outflow obstruction

- after ingestion of wood glue in a dog.  
*J. Am. Anim. Hosp. Assoc.* **39**: 47-51.
- Peppler, C., Amort, M., Thiel, C. and Kramer, M. 2008. Linear foreign body as a cause of ileus in cats- incidence, diagnosis and treatment. *Small Anim. Vet. Pract.* **38**:437-42
- Sluys, F.J.V. 1993. Gastric foreign bodies. Cited in: *Text book of Small Animal Surgery*. (2nd ed). W.B. Saunders Company, Philadelphia, 568 – 571p.
- Uma Rani, R., Vairavasamy, K. and Muruganandan, B. 2010. Surgical management of gastric foreign bodies in pups. *Intas Polivet* **11** (2): 302-303.