

## SURGICAL MANAGEMENT OF EQUINE OCULAR SETARIOSIS – REPORT OF FOUR CASES

Reji Varghese<sup>1\*</sup>, Deny Jennes<sup>2</sup>, Nijin Jos, B. M.<sup>3</sup>, Anoop, S.<sup>4</sup>, Syamala, K<sup>5</sup>.,  
Soumya Ramankutty<sup>6</sup>, Sudheesh S. N.<sup>7</sup>, Abhiram, M. J.<sup>8</sup> and John Martin K. D.<sup>9</sup>

<sup>1,3,5,6,7</sup>Assistant Professor, <sup>2</sup>Ph.D. Scholar, <sup>8</sup>M.V.Sc. Scholar, <sup>4,9</sup>Professor and Head,  
<sup>1</sup>Teaching Veterinary Clinical Complex, <sup>2,3,6,7,8,9</sup>Department of Veterinary Surgery and  
Radiology, <sup>5</sup>Department of Veterinary Parasitology, College of Veterinary and Animal  
Sciences, Mannuthy, Thrissur, <sup>4</sup>Department of Veterinary Surgery and Radiology, College  
of Veterinary and Animal Sciences, Pookode, Wayanad, Kerala Veterinary and Animal  
Sciences University, Kerala.

\*Corresponding author: [reji@kvasu.ac.in](mailto:reji@kvasu.ac.in)

### ABSTRACT

Equine ocular setariosis is a serious parasitic condition which causes ocular damage in animals. The present study was aimed to discuss the surgical management and prognosis of ocular setariosis. The affected four horses were presented to Teaching Veterinary Clinical Complex, Mannuthy, with clinical signs like epiphora and corneal cloudiness. The conditions were managed surgically after appropriate anaesthetic administration. All the animals had an uneventful recovery and attained complete corneal clarity.

**Keywords:** Corneal opacity, Equine ocular Setariosis, Surgical management

### INTRODUCTION

Equine ocular setariosis is an important clinical condition that causes cloudiness of the cornea and if untreated, will lead

to impairment of vision in the animal. In horses, the most frequently isolated worms are *Setaria digitata*, *Thelazia lacrymalis*, and *Setaria equina* (Parrah *et al.*, 2004). Normally, adult setaria worms are found in the peritoneal cavity, but in a very rare condition, they can migrate into the eye and central nervous system (Yadav *et al.*, 2006). The affected animals may exhibit increased lacrimation, mild to complete corneal opacity, photophobia and conjunctivitis; if untreated, the final outcome will be the loss of vision (Patil *et al.*, 2012). The condition can appear unilaterally or bilaterally. Unilateral affections are more common and bilateral affections are rare (Buchoo *et al.*, 2005). If the condition is not surgically treated, the dead worms in the anterior chamber of the eye will start to release toxins, which will damage the endothelium of the cornea and thereby develop corneal oedema, development of cataracts,

synechiae, and retinal detachment (Paglia et al., 2004). The treatment of choice for ocular setariosis is the surgical removal of the worm from the anterior chamber (Sharma et al., 2020).

**CASE HISTORY AND OBSERVATIONS**

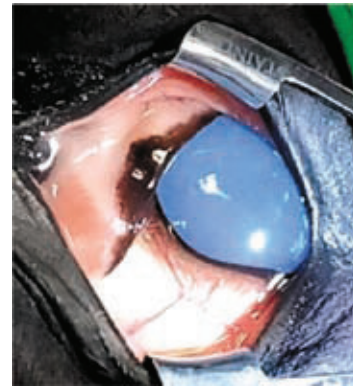Four horses were presented to Teaching Veterinary Clinical Complex, Mannuthy, Thrissur with clinical symptoms of epiphora, blepharospasm, corneal opacity (Fig. 1), impaired vision with visible floating worms in the anterior chamber of the affected eye. The signalment of the cases are presented in table 1. Ophthalmic examination of the affected eye revealed the swirling movement of the white coloured thread like worm in the aqueous humour (Fig. 2). Slit-lamp biomicroscopy was used to evaluate the eye. After ophthalmic examination it was decided to manage the condition surgically under general anaesthesia.

**Table 1.** Signalment of the animals

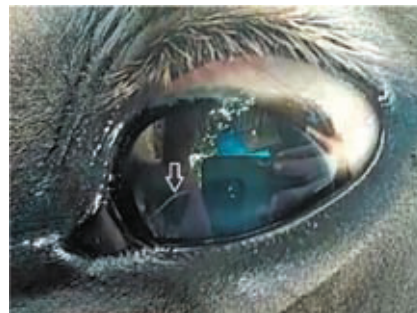SI. No.	Breed	Age (yrs)	Sex	Eye affected
1	Marwari	3	M	Left
2	Kathiawari	3	F	Left
3	Kathiawari	2	M	Left
4	Kathiawari	2.5	M	Left

**TREATMENT**

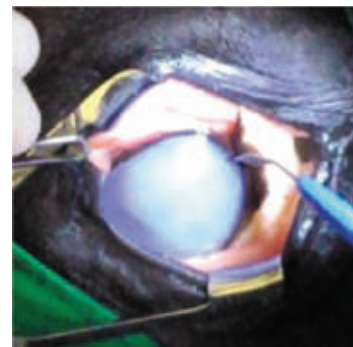All the animals were pre-operatively fasted (food withheld for twelve hours and



**Fig. 1.** Blue eye

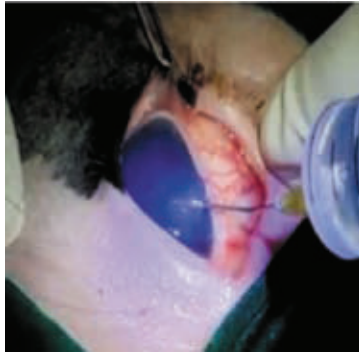


**Fig. 2.** Case 3: A white thread-like worm seen in the eye (arrow)

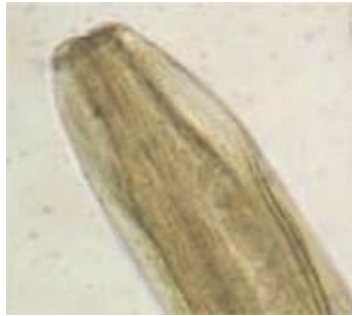

**Fig. 3.** Stab incision of cornea using keratome

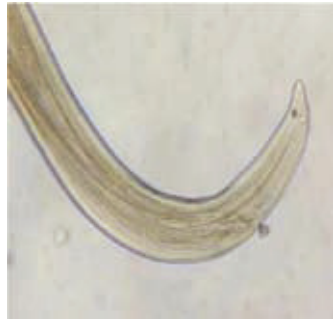water withheld for six hours). The animals were premedicated with inj. xylazine at the rate of 1.1 mg/kg body weight and inj. diazepam at the rate of 0.2 mg/kg body weight intravenously. Induction of anaesthesia was done with inj. ketamine at the rate of 2.2



**Fig. 4.** Needle aspiration of the worm

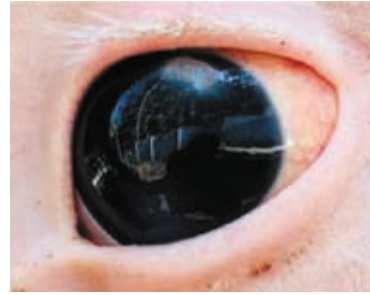

**Fig. 5.** *Setaria equina* - head end of immature female has a peri buccal ring with two crescentic prominences



**Fig. 6.** *Setaria equina* - immature female – tail end ends in a small knob which is smooth

mg/kg body weight intravenously. Animal was restrained in lateral recumbency with affected eye positioned upwards. Prepared the affected eye aseptically with povidone iodine collyrium (1:50). Auriculo-palpebral nerve block was given to prevent the eyelid movements.



**Fig. 7.** Case 2: Complete corneal clarity after three months



**Fig. 8.** Case 3: Complete corneal clarity after one month

The eyelids were retracted using ocular speculum to increase the visibility of the surgical site. By using a sterile keratome a small nick incision was made in the cornea at the level of 1 – 2 o' clock position (Fig. 3) and with the help of a sterile 18G needle aspirated the worm through the nick incision (Fig. 4). For one case, the corneal incision was made using 11 B.P. blade and the worm was flushed out from the anterior chamber. Corneal incision was kept open for postoperative days in three out of four cases and in the case which required a larger incision using the blade, the corneal incision was sutured using polyglactin 910 size 6/0.

Post-operatively the animals were treated with inj. phenylbutazone @ 0.5 mg/

kg intramuscularly for three days, antibiotic ocular eyedrops (Bromifax<sup>TM</sup> - bromfenac 0.09% w/v and moxifloxacin 0.5% w/v) for one week, dexamethasone eye drops for corneal clarity and a dose of albendazole at the rate of 10 mg/kg body weight per orally.

The worms were collected in 70% isopropyl alcohol for the parasitological examination. All four worms were identified as immature female *Setaria equina* species and the worms had an approximate length of 20 mm (Fig. 5 & 6). All the animals acquired complete corneal clarity by three months (Fig. 7 & 8).

## DISCUSSION

*Setaria equina* adult worms are normally present in the peritoneal cavity of the animal and non-pathogenic to the host. But the aberrant migration of the immature larvae to various sites like pleural cavity, testicle, bladder wall and the anterior chamber of the eye will cause complications to the host animal (Liang & Sheng, 1959). The parasite has also been reported in the subconjunctival nodule of the eye of the horse (Regnier *et al.*, 2019). *Setaria* is a roundworm and usually the infection is transmitted through the mosquitoes (Al-Azawi *et al.*, 2012). The most common *Setaria* species which cause ocular disorder in hoofed animals in Asia is the *Setaria*

*digitata* (Penga *et al.*, 2019). Anoop *et al.* (2018) also reported the occurrence of ocular seteriosis (*Setaria digitata*) and its surgical retrieval in a horse. The parasitological examination in the present cases revealed the presence of *Setaria equina* indicating its prevalence in Kerala. The pathogenesis of the ocular worm infection is that, the swirling movement of the parasite in the anterior chamber of the affected animal's eye will cause the inflammation and due to its serrated cuticle, the movement cause traumatic damage to the cornea especially in the corneal endothelium (Jaiswal *et al.*, 2006).

For the surgical removal of the worm from the anterior chamber, the needle aspiration technique was the simplest, fast and inexpensive method (Singh *et al.*, 1976). Peng *et al.* (2019) successfully removed the *Setaria digitata* worm from the anterior chamber of the eye with the help of an 18G needle at 7 o'clock position in the limbus. The pressure created by the aqueous humour towards the needle puncture site will help for the aspiration procedure and through the same method Marzok and Desouky (2009) successfully removed the *Setaria equina* parasites from donkeys through 10 o'clock position. Needle paracentesis method at 1 o'clock position was also suitable for the retrieval of the worm from the anterior chamber

(Rahman *et al.*, 2017). In the present study the parasite was recovered through needle aspiration at 1 – 2 o' clock position.

Medical management of the condition was also reported. According to Muhammad and Saqib (2007), the microfilaremia was resolved with a single subcutaneous injection of ivermectin at a dose rate of 300 µg/kg body weight after 7 days and the ocular signs disappeared after 90 days. Mohite *et al.* (2020) also reported medical management of equine ocular setariosis with oral ivermectin at a dose rate of 0.6 mg/kg body weight at the interval of four days up to the immobilisation of the worm. The spread of setariosis could be prevented through the proper vector control. The breeding sites of mosquitoes near the stable could be destroyed. The stables could be covered with mosquito nets to prevent the mosquito bites in endemic areas. Mosquito repellent pour-on can be applied over the body of the horse. Due to the short duration of action, it is not likely to give protection for long (Laaksonen *et al.*, 2008).

In the present case report, all the animals showed epiphora, complete corneal opacity and conjunctivitis with impaired vision. Worm movements were noticed inside the anterior chamber in all four cases and it could be clearly visible in slit lamp biomicroscopy. The surgical management

which included nick incision of cornea and needle aspiration, yielded good results and helped to restore the clarity of the cornea. The importance of vector control was explained to the clients.

## CONCLUSION

Ocular setariosis is a condition causing vision impairment in horses. Timely diagnosis and treatment are a key to a favourable outcome. Four such cases were successfully treated with corneal nick incision and needle aspiration of the worm. The worms were identified as *Setaria equina*. All the animals acquired normal vision without any complications.

## ACKNOWLEDGEMENT

The authors are thankful to the Dean, College of Veterinary and Animal Sciences, Mannuthy and Professor and Head, Teaching Veterinary Clinical Complex, Mannuthy, Thrissur for providing required facilities for the completion of the work.

## REFERENCES

- Al-Azawi, K.A., Fadhl, R.A. and Fadhl, R.S., 2012. Epidemiological study of *Setaria equina* infection in donkeys. *Iraq. Vet. J.* **36**: 93–97.
- Anoop, S., Athira, V.P., Vysakh, V., Abhijith, M.S., Thajunnisa, A.S., Soumya,

- R., Sudheesh, S.N. and Devanand, C.B., 2018. Ocular setariasis and its surgical retrieval in a horse- a case report. *Indian Vet. J.*, **95**: 88-89
- Buchoo B.A., Pandit, B.A., Shahardar, R.A., Parrah, J.D. and Darzi, M.M. 2005. Surgical management and prevalence of ocular filariasis in equines. *Indian Vet. J.* **82**:81-82.
- Jaiswal, S., Singh, S.U., Singh, B., and Singh, H.N. 2006. Ocular setariosis in a horse. *Intas Polivet.* **7**:67-68.
- Laaksonen, S., Oksanen, A., Orro, T., Norberg, H., Nieminen, M. and Sukura, A., 2008. Efficacy of different treatment regimes against setariosis (*Setaria tundra*, Nematoda: Filarioidea) and associated peritonitis in reindeer. *Acta Vet. Scand.* **50**: 49.
- Liang Sheng, Y. 1959. A revision of the nematode genus *Setaria* Viborg, 1795, its host-parasite relationship, speciation and evolution. *J. Helminthol.* **33**:1-98.
- Marzok, M.A. and Desouky, A.Y. 2009. Ocular infection of donkeys (*Equus asinus*) with *Setaria equina*. *Trop. Anim. Health Prod.* **41**:859-863.
- Mohite, D.S., Sheikh, C.S., Williams, S.D. and Compston, P.C. 2020. Evaluation of medical management of ocular setariosis in equids in India. *Indian Vet. J.* **97**: 53 – 55.
- Muhammad, G. and Saqib, M., 2007. Successful treatment of ocular equine microfilariasis (*Setaria* species) with ivermectin. *Vet. Rec.* **160**: 25-26.
- Penga, T.L., Armiladianab, M.M., Ruhila, H.H., Maizana, M. and Choong, S.S. 2019. First report of equine *Setaria digitata* (von Linstow 1906) infestation in Malaysia. *Vet. Parasitol. Reg. Stud. and Rep.* **17**: 1-5.
- Paglia, D.T., Miller, P.E. and Dubielzig, R.R. 2004. James Wardrop and equine recurrent uveitis. *Arch. Ophthalmol.* **122**:1218-1223.
- Parrah, J.D., Buchoo, B.A. and Moulvi, B.A. 2004. Ocular filariasis in equines: A study of 9 cases. *Centaur.* **4**:70-71.
- Patil, D.B., Parikh, P.V., Joy, N., Jhala, S.K., Dar, M.U.D. and Tiwari, D.K. 2012. Equine eye worm: a review of 50 cases. *Indian J.Vet. Surg.* **33**:61-62.
- Rahman, M., Rana, E.A., Tanvir, M.I., Sabuj, A.A., Imtiaz, M.A. and Hasan, T. 2017. A case study on needling technique as a treatment for ocular setariasis in eye of a horse. *Asian J. Med. Biol. Res.* **3**: 398-404.

- Regnier, A., Martin, C., Semin, M., Lienard, E., Geffre, A., Douet, J. and Raymond Letron, I. 2019. Subconjunctival nodule due to *Setaria equina* erratic migration in a horse: First case report. *Vet. Ophthalmol.* **2019**:1–7.
- Sharma, S., Saini, D., Arora, N., Tiwari, D.K., Tikoo, A. and Singh, B. 2020. Surgical management of ocular setariosis in stallion. *J. Entomol. Zool. Stud.* **8**: 1953-1955.
- Singh, H., Chaudhuri, P.C., and Kumar, A. 1976. Paracentesis oculi: a preferred technique for removal of intraocular parasites in horses. *Indian Vet. J.* **53**:467-468.
- Yadav, A., Kumar, A., Bhadwal, M.S., Khajuria, J.K. and Gupta, A. 2006. Ocular setariosis in horses: A case study. *J. Vet. Parasitol.* **20**:1-10.