

---

## FELINE PYOMETRA AND ITS SURGICAL MANAGEMENT: A CASE REPORT

Sudheesh S. Nair<sup>1\*</sup>, Deny Jennes<sup>2</sup>, Soumya Ramankutty<sup>1</sup>,  
Anoop S.<sup>3</sup> and John Martin K. D.<sup>4</sup>

*Assistant Professor<sup>1</sup>, MVSc. Scholar<sup>2</sup>, Associate Professor, Professor and Head<sup>3</sup>  
Department of Veterinary Surgery and Radiology  
College of Veterinary and Animal Sciences, Mannuthy, Thrissur-680651  
\*Corresponding author: sudheeshnair@kvasu.ac.in*

---

### ABSTRACT

A three year old female crossbred cat was presented to University Veterinary Hospital, Mannuthy with distended abdomen and history of draining of pus discharge from vagina. On ultrasonographic examination, hypoechoic contents in dilated uterus were appreciated. The pus from the uterus was subjected to culture and sensitivity which confirmed gram negative rods. The case was surgically managed by ovario-hysterectomy. The animal had an uneventful recovery.

**Keywords:** Feline, Pyometra, Progesterone, Ovario-hysterectomy

### INTRODUCTION

Pyometra in cats is defined as an acute or chronic suppurative inflammatory disorder of the uterine wall in intact queens characterised by the accumulation of pus in uterine lumen (Hollinshead and

Krekeler, 2016). Queen is an induced ovulator, and ovulation occurs 30 to 50 hours after coitus. The corpora lutea in queens starts to produce progesterone 24 to 48 hours after the ovulation (Holt *et al.*, 2003). The pyometra often results from influence of hormone progesterone that causes hyperplasia and increased secretory activity of endometrial glands (Lawler, 1995). Decreased myometrial contractility in pyometra hastens the ascending bacterial infection from vagina (Barsanti, 1998). The condition is often diagnosed symptomatically by discharge of pus as in open pyometra. Ultrasonography is an effective tool for identifying pus filled uterus which could be identified as hypoechoic contents in dilated uterus. Early ovario-hysterectomy is advised for the management of this condition. Ovario-hysterectomy is curative and preventive for recurrence with anticipated risk of anaesthesia and post spaying sterility.

**CASE HISTORY AND OBSERVATIONS**

A three year old female crossbred queen cat weighing 4.5 kg presented to Teaching Veterinary Clinical Complex, Mannuthy with anorexia, polydipsia, polyuria and pus discharge from the vagina (Fig.1). The animal had a history of mating before 60 days. Physiological parameters including rectal temperature, respiration and heartrate were within the normal limits. Complete blood count revealed leucocytosis, granulocytosis, lymphopenia, anemia and thrombopenia (Table1). Serum biochemistry revealed increased creatinine value. On ultrasonographic examination, hypoechoic area presented within the uterine lumen was suggestive of pyometra (Fig. 2).

**TREATMENT AND DISCUSSION**

Culture and sensitivity of the pus sample collected from the uterus after surgery revealed Gram negative bacilli.

Sensitivity test revealed the rods sensitive to amoxicillin, tetracycline, and gentamicin (Fig. 3).

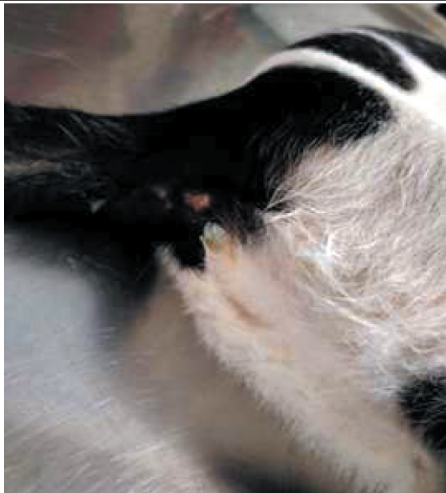The anaesthesia was induced with combination of inj. ketamine @ 25 mg/kg B.W. and inj. diazepam 0.5 mg/kg B.W. intramuscularly. Anaesthesia was maintained with isoflurane 1%- 2% in oxygen with face mask. A linear mid ventral incision was made and severely enlarged uterine horns were carefully exteriorized. Ovariohysterectomy was performed in routine manner with careful precautions to prevent the spillage of uterine contents (Fig. 4).

Post operatively inj. amoxirum forte @ 12.5 mg/kg B.W. twice daily was administered for seven days along with suspension meloxicam (1.5 mg/ml) @ 0.2 mg /kg B.W. once daily for three days and multivitamin drops . On tenth postoperative day the sutures were removed. Animal had an uneventful recovery.

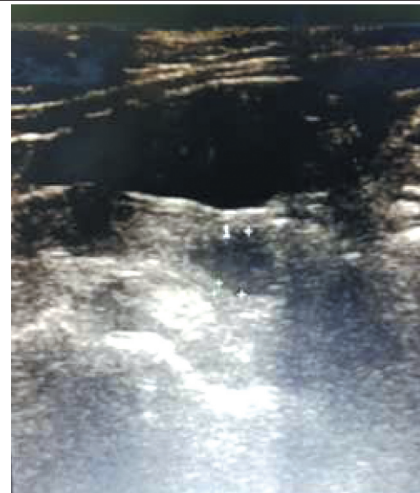
The pyometra is a rare condition in cats because of low progesterone

**Table 1 Haematobiochemical changes in pyometra**

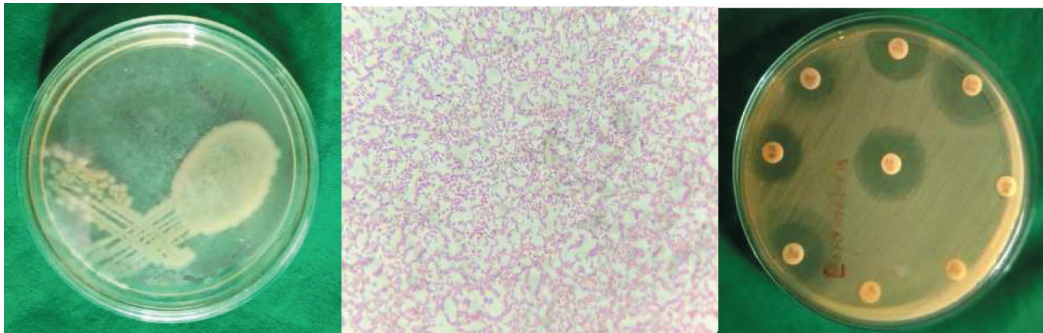
Parameters	Cat (with pyometra)	Normal limits
WBC (10 <sup>3</sup> / μl)	27.3	5.5 – 19.5
Lymphocytes (10 <sup>3</sup> /μl)	5.2	1.1- 10.7
Monocytes (10 <sup>3</sup> /μl)	0.7	0.1- 0.8
Granulocytes (10 <sup>3</sup> /μl)	22	3.6- 12.7
RBC (10 <sup>6</sup> /μl)	4.32	5- 10
Haemoglobin (g/dl)	6.8	8-15
Platelet (10 <sup>3</sup> /μl)	63	160-660
Creatinine (mg/dl)	2	0.5-1.5



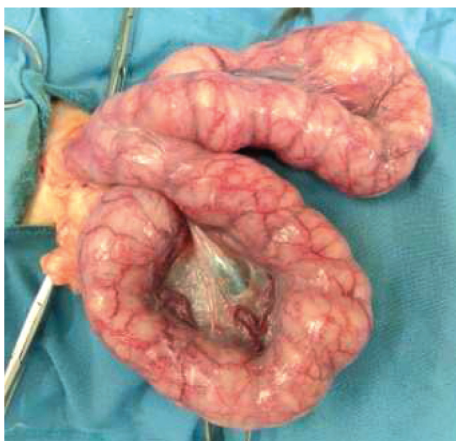
**Fig. 1.** Pus discharge from uterus



**Fig. 2.** Ultrasonographic findings



**Fig. 3.** Bacterial culture and antibiogram



**Fig. 4.** Uterus after exteriorisation

dominance due to seasonality and induced ovulation (Hagman *et al.*, 2014). In case pyometra of queen, most commonly isolated bacteria reported were *E. coli*,

*Staphylococcus aureus*, *Klebsiella* species, *Proteus* species and *Streptococcus* species. Ascending infection of faecal bacteria through vagina during oestrus when the cervix is relaxed is the most common cause of pyometra (Wadas *et al.*, 1996). In cats, the identification of the condition is very difficult because the cats are fastidious groomers who generally clean the vulval discharge before it could be noticed by the owner. This often leads to delay in the diagnosis. Cats with closed cervix pyometra will show systemic illness and absorption of bacterial toxins which could

result in endotoxaemia and bacteraemia (Hollinshead and Krekeler, 2016). The hormone progesterone was identified as most important factor for the proliferation of endometrial glands, increased secretion, cervical closure and suppression of myometrial contractions (Cox, 1970). Cystic endometrial hyperplasia could increase the uterine susceptibility to the infections (England *et al.*, 2012).

Endotoxins, lipopolysaccharides of gram negative bacteria released into the circulation during the process of bacterial disintegration could lead to fever, lethargy, tachycardia and tachypnea (Van Miert and Frens, 1968). Higher concentration of endotoxins results in fatal shock, disseminated intravascular coagulation and generalized organ failure (Okano *et al.*, 1998). Pyometra also found to cause liver and kidney damage (Kenney *et al.*, 1987). Ultrasonography is the most efficient diagnostic modality for pyometra as it helps to detect the intrauterine fluid. The differential diagnosis of pyometra in cats includes mucometra, hydrometra and haemometra (Bigliardi *et al.*, 2004). Early management is the key to save the life of the patient. Ovario-hysterectomy is the most effective treatment of choice because through surgical management source of infection and bacterial products are removed and recurrence also prevented (Hardy and

Osborne, 1974). In the present case timely ovario hysterectomy and precise antibiotic therapy based on a culture and sensitive test saved the life of the cat.

### SUMMARY

A case report of open cervix pyometra in a queen cat and its successful surgical management and uneventful recovery is reported.

### ACKNOWLEDGMENT

The authors are thankful to Dean, College of Veterinary and Animal Sciences, Mannuthy .

### REFERENCES

- Barsanti, J. A. 1998. Genitourinary infections. In: *Infectious diseases of the Dog and Cat*. (2<sup>nd</sup> Ed.). C. E. Green. W. B. Saunders Company, Philadelphia. pp. 643-644.
- Bigliardi, E., Parmigiani, E., Cavarani, S., Luppi, A., Bonati, L and Corradi, A. 2004. Ultrasonography and cystic hyperplasia- pyometra complex in the bitch. *Reprod. Domest. Anim.* **39**: 136-140.
- Cox, J. E. 1970. Progestagens in bitches: a review. *J Small Anim Pract.* **11**: 759-78.
- England, G. C., Moxon, R. and Freeman, S. L. 2012. Delayed uterine fluid

- clearance and reduced uterine perfusion in bitches with endometrial hyperplasia and clinical management with postmating antibiotic. *Theriogenology*, **78**: 1611-1617.
- Hagman, R., Holst, B. S., Moller, L. and Egenvall A. 2014. Incidence of pyometra in Swedish insured cats. *Theriogenology*, **82**: 114-120.
- Hardy, R. M. and Osborne, C. A. 1974. Canine pyometra: pathophysiology, diagnosis and treatment of uterine and extra-genital lesions. *J. Am. Anim. Hosp. Assoc.* **10**: 245-268.
- Hollinshead, F., and Krekeler, N. 2016. Pyometra in the queen to spay or not to spay?. *J. Feline Med. Surg.* **18**: 21-33.
- Holt, B. S., Bergstrom, A., Lagerstedt, A. S., Karlstam, E., Englund, L and Baverud, V. 2003. Characterization of the bacterial population of the genital tract of adult cats. *Am. J. Vet. Res.* **64**: 963-968.
- Kenney, K. J., Matthiesen, D. T. Brawon, N. O. and Bradley, R. L. 1987. Pyometra in cats: 183 cases (1979-1984). *J. Am. Vet. Med. Assoc.* **191**: 1130.
- Lawler, D. F. and Johnston, S. D. 1995. Complications of the non ovulatory copulation in the queen. In: J. D. Bonagura and R. W. Kirk. (ed.), *Current Veterinary Therapy* (12<sup>th</sup> Ed.) W. B. Saunders Co. Philadelphia. pp. 1166-1167.
- Okano, S., Tagawa, M. and Takase, K. 1998. Relationship of the blood endotoxin concentration and prognosis in dogs with pyometra. *J. Vet. Med. Sci.* **60**: 1265-1267.
- VanMiert, A. S. J. and Frens, J. 1968. The reaction of different animal species to bacterial pyrogens. *Zentralbl Veterinarmed A.* **15**: 532-543.
- Wadas, B., Kuhn, I., Lagerstedt, A. S. and Jonsson, P. 1996. Biochemical phenotypes of *Escherichia coli* in dogs: comparison of isolates isolated from bitches suffering from pyometra and urinary tract infection with isolates from faeces of healthy dogs. *Vet. Microbiol.* **52**: 293-300.
-