

## THERAPEUTIC MANAGEMENT OF DILATED CARDIOMYOPATHY IN A LABRADOR RETRIEVER DOG

Swathi S.<sup>1</sup>, Ajithkumar S.<sup>2\*</sup>, Vishnurahav R.B.<sup>3</sup> and Usha Narayana Pillai<sup>4</sup>

<sup>1</sup>MVSc student, <sup>2</sup>Professor and Head, Department of Veterinary Clinical Medicine, Ethics and Jurisprudence, CVAS, Pookode <sup>3</sup>Teaching Assistant <sup>4</sup>Professor and Head, Department of Veterinary Clinical Medicine, Ethics and Jurisprudence, College of Veterinary and Animal Sciences, Mannuthy, Thrissur, Kerala – 680651  
\*Corresponding author: [ajithkumar@kvasu.ac.in](mailto:ajithkumar@kvasu.ac.in)

### ABSTRACT

A six and half year-old female Labrador retriever dog was presented to Teaching Veterinary Clinical Complex, Mannuthy with the complaint of anorexia, cough, weight loss, increased water intake and exercise intolerance. On clinical examination pale mucous membrane, dyspnoea, pulmonary crackles and cardiac murmurs on auscultation were observed. Thoracic radiograph revealed cardiomegaly, left atrial enlargement and pulmonary oedema. Increase in the duration of P wave (P wave width 0.06sec) was observed in electrocardiogram. Dilated cardiomyopathy was confirmed by echocardiography on the basis of left atrial and ventricular enlargements, increased left atrium/ aorta (LA: Ao) ratio, decreased systolic ejection fraction and fractional shortening. The animal was treated with furosemide (2mg/kg/q12h), enalapril (0.5mg/kg/q12h) and Top 10<sup>®</sup>,

multivitamin, minerals and trace elements tablet orally. Condition of the animal was improved with the treatment.

**Keywords:** Canine, Dilated cardiomyopathy, Echocardiography, Management

### INTRODUCTION

Dilated cardiomyopathy (DCM) is a common condition causing heart failure in dogs. It is a disease of heart muscle, characterized by dilatation of cardiac chambers, systolic dysfunction and clinical signs of congestive cardiac insufficiency (Martin *et al.*, 2009). Aetiology of this condition is multifactorial, which includes genetic, nutritional (L- carnitine or taurine deficiencies), oxidative stress, hypothyroidism, diabetes mellitus etc. It can also occur as idiopathic (Tidholm *et al.*, 2001). It is prevalent in large breeds of dogs like Doberman, Labrador retriever, German shepherds, Great Dane and

Boxers. The prognosis is usually poor for symptomatic DCM and the median survival time after diagnosis in DCM affected Irish Wolfhounds with congestive heart failure signs and atrial fibrillation was 7.3 months (Vollmar *et al.*, 2019). Quality of life and survival period of affected dogs could be improved with proper treatment.

**CASE HISTORY AND OBSERVATIONS**

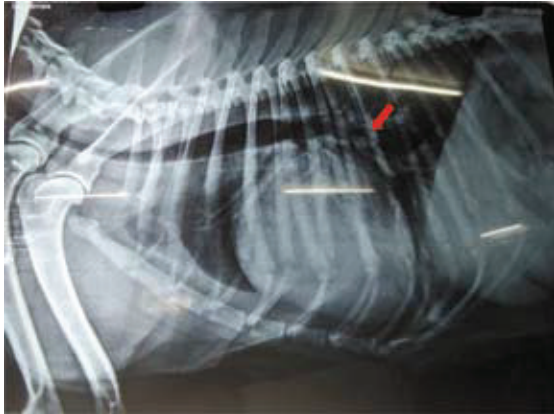
A six and half year-old female Labrador retriever dog was presented to Teaching Veterinary Clinical Complex, Mannuthy with the complaint of anorexia, cough, weight loss, increased water intake and exercise intolerance for 14 days. Owner reported that the dog was previously treated with antibiotic and chlorpheniramine maleate, but there was no improvement in condition. Pale mucous membrane, dyspnoea, pulmonary crackles and cardiac murmurs on auscultation were observed during the clinical examination. Haemato-biochemical analysis showed, microcytic anaemia and granulocytosis, with normal levels of blood urea nitrogen, serum creatinine and alanine aminotransferase. Radiographic examination of thorax revealed tracheal elevation, left atrial enlargement, pulmonary oedema and cardiomegaly with increased vertebral heart score (VHS) of 12.5 (Fig.1). Increase

in P wave duration (0.06sec) was observed in electrocardiography, indicating left atrial enlargement. Left atrial and ventricular enlargements, increased left atrium/ aorta (LA: Ao) ratio of 1.61 (Fig. 3), hypokinesis of left ventricular wall in M mode (Fig. 2), decreased systolic ejection fraction (25 per cent) and fractional shortening (12 per cent) were observed during echocardiography. As per Table.1, increased left ventricular internal dimension in systole (LVID<sub>s</sub> 54.4 mm) and left ventricular internal dimension in diastole (LVID<sub>d</sub> 61.7 mm) were observed, which suggested left ventricular dilatation. Considering all these findings, the animal was diagnosed as dilated cardiomyopathy (DCM).

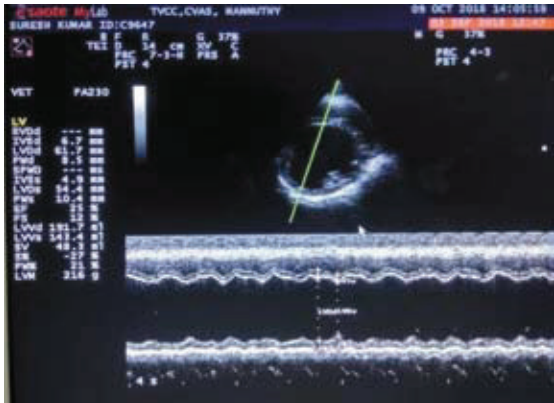
**Table 1. M mode echocardiographic parameters from the Labrador retriever with DCM and normal values in healthy Labrador retriever dogs**

VARIABLE	VALUES	NORMAL VALUE*
LVID <sub>s</sub> (mm)	<b>54.4</b>	14.5-36.8
LVID <sub>d</sub> (mm)	<b>61.7</b>	29.4-45.3
IVS <sub>s</sub> (mm)	<b>4.9</b>	8.1-20.8
IVS <sub>d</sub> (mm)	6.7	5.6-13.5
PW <sub>s</sub> (mm)	10.4	9.1-14.7
PW <sub>d</sub> (mm)	8.5	6.2-11.3
EF (%)	<b>25</b>	45.45-81.35
FS (%)	<b>12</b>	18.75-49.66
LA/Ao	<b>1.61</b>	0.78-1.23

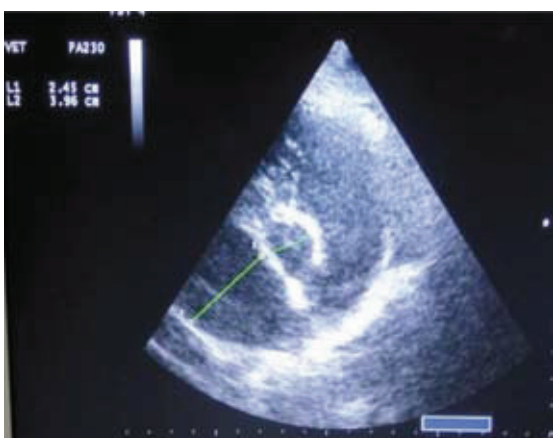
\*Normal values as per (Gugjoo *et al.*, 2014)



**Fig.1.** Right lateral thoracic radiograph showing cardiomegaly, left atrial enlargement (arrow) tracheal elevation, pulmonary oedema and increased vertebral heart score of 12.5.



**Fig. 2.** B mode echocardiography with right parasternal, short axis view of left ventricle and corresponding M- mode showing dilated left ventricle with hypokinetic walls.



**Fig.3.** Right parasternal short axis echocardiographic view of the aorta and left atrium with LA/Ao ratio of 1.61

## TREATMENT AND DISCUSSION

The dog was treated with oral administration of amoxicillin clavulanate (12.5mg/kg/q12h) for seven days and continuous daily oral therapy using ACE inhibitor enalapril (0.5mg/kg/q12h), furosemide (2mg/kg/q12h) and Top 10<sup>®</sup> multivitamin, minerals and trace elements tablets (1tab/q12h). Examination was performed monthly for 4 months, for evaluating the disease condition and monitoring of therapy. Animal started taking food and the clinical signs subsided after two weeks of treatment. Spironolactone was added with furosemide after two weeks along with ACE inhibitor and multivitamins.

Dilated cardiomyopathy is the most common acquired cardiac disease in dogs. According to Alves *et al.* (2012), more frequent occurrence of DCM was observed in dogs of 4-10 years of age. Based on clinical history, breed susceptibility, radiography and echocardiography the case was diagnosed as DCM. Decreased ejection fraction and fractional shortening, observed in this case might be due to impaired cardiac contraction induced by the myofibrillar degeneration and fibrotic infiltration (Sisson, 2002). Angiotensin converting enzyme (ACE) inhibitors like enalapril act by lowering blood pressure and reducing the resistance to the blood

flowing out of the heart. Furosemide stimulates the kidneys to remove excess fluid from the body and reduces the preload of the heart. Even though the drug of choice for the treatment of DCM with congestive heart failure is pimobendan (an inodilator), it was not instituted in the treatment protocol due to the financial inability of the pet owner.

### SUMMARY

Dilated cardiomyopathy was diagnosed in a six and half year-old female Labrador retriever dog with anorexia, cough, weight loss, and exercise intolerance using electrocardiography, radiography and echocardiography. The animal was treated with Enalapril as ACE inhibitor, and furosemide as initial diuretic, followed by combination of furosemide and spironolactone.

**Ethics statement:** This study does not involve animal experimentation and was conducted on cases reported in the hospitals, following standard operating protocols of animal handling and sample examination, upon informed consent of owners.

### REFERENCES

- Alves, R.D.O., Torres, A.C.B, Mantovani, M.M, Carneiro, S.C.D.M.C, Silva, L.H, Pires, H.C.M, Costa M.V. and Cerqueira, A.B. 2012. Dilated cardiomyopathy in boxer puppy of eight months of age: a case report. *Biosci. J.* **28**: 842-845.
- Gugjoo, M.B., Hoque, M., Saxena, A.C., Shamsuz, Z.M.M. and Dey, S. 2014. Reference values of M-mode echocardiographic parameters and indices in conscious Labrador Retriever dogs. *Iran J. Vet. Res.* **15**: 341-346.
- Martin, M.W.S., Johnson, M.J. and Celona, B. 2009. Canine dilated cardiomyopathy: a retrospective study of signalment, presentation and clinical findings in 369 cases. *J. Small Anim. Pract.* **50**: 23-29.
- Sisson, D. 2002. Myocardial diseases of dog. In: *Textbook of canine and feline cardiology: Principles and clinical practice*. Saunders, Philadelphia. 1999p.
- Tidholm, A., Haggstrom, J., Borgarelli, M. and Tarducci, A. 2001. Canine idiopathic dilated cardiomyopathy. Part I: Aetiology, clinical characteristics, epidemiology and pathology. *Vet. J.* **162**: 92-107.
- Vollmar, C., Vollmar, A., Keene, B.W., Fox, P.R., Reese, S. and Kohn, B. 2019. Dilated cardiomyopathy in 151 Irish Wolfhounds: Characteristic clinical findings, life expectancy and cause of death. *Vet. J.* **245**: 15-21.

---

## A RARE CASE OF CYCLOPIA AND ARHINIA IN A GOAT KID

John A.M.<sup>1\*</sup>, Karthik A.<sup>1</sup>, Francis J.<sup>1</sup>, Xavier Mathew<sup>2</sup> and Preena P.<sup>3</sup>

<sup>1</sup>Veterinary Hospital, Channapetta, Kollam, <sup>2</sup>Department of Veterinary Epidemiology and Preventive Medicine, CVAS, Pookode, <sup>3</sup>District Veterinary Centre, Kannur  
Veterinary Hospital, Channapetta, Kollam, Department of Animal Husbandry, Kerala  
Corresponding author: [anniemariamjohn@gmail.com](mailto:anniemariamjohn@gmail.com)

---

### ABSTRACT

A rare form of cyclopia and arhinia was described in a kid born to a one and half year old primiparous Malabari eutocic doe. The most significant craniofacial malformation was the presence of a single median orbit that contained a single, large exophthalmic eyeball lacking vision. The congenital changes were confined to the head of the kid. The kid showed multiple birth defects like eyelid agenesis, arhinia and prognathism. The possible cause of this congenital defect could not be ascertained.

**Keywords:** Craniofacial anomaly, Eutocia, Goat, Malabari, Kerala

### INTRODUCTION

Congenital malformations usually occursporadicallyinanimalsandmayrequire veterinarian's intervention and guidance (Agerholm *et al.*, 2015). Holoprosencephaly (HPE) is the failure of forebrain to separate normally into two discrete cerebral

hemispheres. Cyclopia or circle eye is a rare form of holoprosencephaly which is characterized by the failure of the embryonic prosencephalon to properly divide the orbits of the eye into two cavities (Sutaria *et al.*, 2012). Cyclops or cyclopia or cebocephalus also refers to gross malformations of the central nervous system, characterized by a single median orbital fossa in which global tissue is absent or rudimentary. Eyeball may be absent or ranging from a single, almost perfect eyeball through all degrees of doubling to two complete and closely adjacent globes of reduced size (Sivasudharsan *et al.*, 2010). Cyclopia has been previously reported in cattle (Nourani *et al.*, 2014), buffalo (Singh *et al.*, 2013), pigs (Autade *et al.*, 2012) and goats (Sivasudharsan *et al.*, 2010). Congenital arhinia is another rare anomaly consisting of an absence of external nasal structures and nasal passages. Inherited genetic abnormalities, viral infections, hypovitaminosis, and teratogens such as



radiation and plant toxins were attributed to be the problems in the embryonic forebrain dividing process, leading to development of such foetal monsters (Ozcan *et al.*, 2006). HPE and other related craniofacial deformities in lamb foetuses, 'monkey face lamb disease', were produced when pregnant ewes in early gestation grazed on *Veratrum californicum*, which contain a highly teratogenic alkaloid toxin called cyclopamine or 2deoxyjervine (Welch *et al.*, 2009; Sutaria *et al.*, 2012). The present case study puts on record a rare occurrence of cyclopia with arhinia in a kid delivered normally.

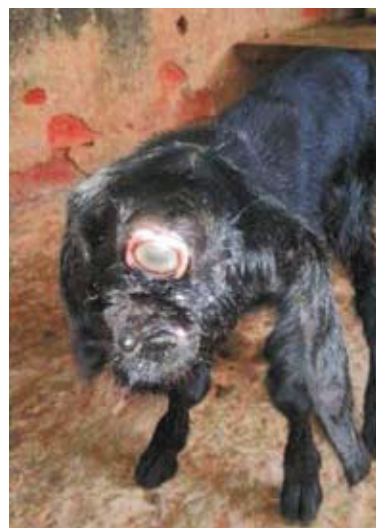#### CASE HISTORY AND OBSERVATION

A one and half year old apparently healthy primiparous Malabari goat delivered a single normal sized, male live kid in normal anterior longitudinal presentation without any external assistance. The most striking feature of the kid was the presence of a single median orbit that contained a large exophthalmic eyeball lacking vision (Fig. 1). The craniofacial area was normal sized but severely deformed. Absence of eyelids, eyelashes, muzzle, external nasal structures and nasal passages or the skeletal structures of nose were also noted. The upper and lower lips were deformed with a narrow oral opening. The short upper jaw with deformed maxilla without os incisivum and large prominent protruded

lower jaw was also observed. Dental pad or upper incisors were also noted to be absent. A well-formed normal sized tongue was present which was mostly protruding from the oral cavity. The kid did not show any abnormalities of neck, vertebrae, thorax, abdomen or limbs. The kid was unable to find the udder due to blindness and failed to suckle the dam. When colostrum was hand fed, inability to swallow was also detected. Later the kid developed respiratory distress and could survive only for three days.

#### TREATMENT AND DISCUSSION

Sivasudharsan *et al.* (2010) stated that teratological features had long been identified as a cause of dystocia in animals and human, however in the present case the kid delivered without any assistance. The physical characteristics of the eye were suggestive of the condition known as



**Fig. 1.** Cyclopic kid's head showing a single median orbit-like opening with a single eyeball.

cyclopia. Other prominent morphological defects of the kid include eyelid agenesis, arhinia and prognathism. All the physical characteristics of the deformed fetus in the present study could be classified under teratological defects of embryonic development (Noakes *et al.* 2018). As the congenital disorders are incompatible with life, no medical or surgical treatment was done in the present case. Similar to the present study, cyclopia with other cephalic congenital abnormalities like arrhinocephaly, anostomia, aglossia and anencephaly has been reported by Mahabady and Barati (2012). An atypical cyclopic monster with arhinic condition in a buffalo was reported by Patel *et al.* (2019). A report of multiple birth defects like synophthalmia, arhinia, hypoplastic maxilla, curved mandibles and dental pad agenesis in a female Holstein calf was published by Nourani *et al.* (2014) similar to the present study. A rare teratological case of schistosomus reflexus and cyclopia syndromes causing dystocia were reported in a Tellicherry doe (Sivasudharsan *et al.*, 2010).

In the present case, there was no previous history of dam's disease conditions, treatment history and type of plants fed, as the dam was purchased from market during its late pregnancy. Hence, the

causative agent for this congenital defect could not be ascertained. This warrants a detailed investigation for procuring further information about the etiology of this malformation. This could be achieved by genetic analysis of the dam and sire of the affected fetus and detailed investigation of exposure of the dam to various teratological insults during the early gestation which could have caused cyclopia in the kid (Singh *et al.*, 2013; Patel *et al.*, 2019). The identification of the specific causative agent of the congenital disorder may ensure the preventive measures of such incidents in future.

#### ACKNOWLEDGEMENT

Authors are grateful to the Director, Dept. of Animal Husbandry, Kerala for providing the required facilities.

**Ethics statement:** This study does not involve animal experimentation and was conducted on cases reported in the hospitals, following standard operating protocols of animal handling and sample examination, upon informed consent of owners.

#### REFERENCES

- Agerholm, J.S., Hewicker-Trautwein, M., Peperkamp, K. and Windsor, P.A. 2015. Virus induced congenital malformations in cattle. *Acta Vet. Scand.* **57**(1): 54.

- Autade, D.P., Markandeya, N.M. and Deshmukh, N.D. 2012. Cyclopic monster in a sow. *Intas Polivet*. **13**(1): 159-160.
- Mahabady, M.K. and Barati, F. 2012. Multiple congenital cephalic defects in a calf. *Asian J. Anim. Vet. Adv.* **7**(8): 767-770.
- Noakes, D.E., Parkinson, T.J. and England, G.C. 2018. *Arthur's Veterinary Reproduction and Obstetrics-E-Book*. Elsevier Health Sciences, England. Pp 128-136.
- Nourani, H., Karimi, I. and Vardanjani, H.R. 2014. Synophthalmia in a Holstein cross calf. *Vet. Res. Forum*. **5**(4): 333-335.
- ÖZcan, K., Gürbulak, K., Takci, I., ÖZEn, H., Kaçar, C. and Pancarci, M.Ş. 2006. Atypical cyclopia in a brown swiss cross calf: a case report. *Anat. Histol. Embryol*. **35**(3): 152-154.
- Patel, A., Kumar, B., Sachan, V., Yadav, S., Yadav, D., Kumar, A. and Saxena, A. 2019. Atypical cyclopia associated with arhinia in buffalo calf and its management through fetotomy. *Buff. Bull*. **38**(1): 159-163.
- Singh, H., Gupta, G., Jan, M.H., Nabi, S.U., Singh, J. and Dey, S. 2013. Atypical cyclopia in a buffalo calf. *Buff. Bull*. **32**(1): 15-17.
- Sivasudharsan, L., Parthiban, S., Pothiappan, P., Karthikeyan, B. and Manimaran, P. 2010. Schistosomus reflexus with cyclopia related foetal dystocia in a Tellicherry doe-case report. *Anim. Sci. Reporter*. **4**(4): 156-159.
- Sutaria, T.V., Sutaria, P.T., Patel, J.S. and Chauhan, P.M. 2012. An unusual case of cyclopic and arhinia monster in Mehsana buffalo. *Vet. World*. **5**(7): 429-430.
- Welch, K.D., Panter, K.E., Lee, S.T., Gardner, D.R., Stegelmeier, B.L. and Cook, D. 2009. Cycloamine-induced synophthalmia in sheep: defining a critical window and toxicokinetic evaluation. *J. Appl. Toxicol*. **29**(5): 414-421.



---

## CANINE DISTEMPER OUTBREAK IN PALM CIVETS AND ITS IMPLICATIONS IN ANIMAL HEALTH

Aparna S., Swapna Susan Abraham\*, Prathiush P.R., Sobha S.S. and  
Jayachandran R.

*State Institute for Animal Diseases, Palode, Thiruvananthapuram, Animal Husbandry  
Department, Kerala*

*\*Corresponding Author: swapnasusan2003@yahoo.co.in*

---

### ABSTRACT

A fatal disease outbreak occurred in palm civets in Thiruvananthapuram district of Kerala, a southern state of India. The disease killed about twenty animals in three localities of the district. Clinical signs were unnoticed and reported as “found dead” in field. Samples collected during post mortem were positive for canine distemper virus antigen using CDV antigen test kit. Consistently observed lesions consisted of severe pneumonia, meningitis, encephalitis and gastroenteritis. Bacteriological culture and antigen detection tests for other infections such as rabies, canine and feline corona infection and parvo viral enteritis were negative. Though not a zoonotic pathogen, the disease has got animal health implications. Being a fatal and highly contagious disease, CDV could threaten their life and endanger the species and also pose a serious threat to the health of pets, stray dogs, zoo animals and wild animals facing species endangerment in the areas they inhabit. The potential of cross-species

disease transmission between wildlife and domestic animals is discussed.

**Key words:** Palm Civet, CDV, Canine Distemper, Epidemic

### INTRODUCTION

Asian palm civet (*Paradoxurus hermaphrodites*) commonly known as Toddy cat of family Viverridae, is a native of India and distributed across Asia. They are commonly exploited for human consumption and hunted for fur, meat or scent in many parts of the world. They have been known as a nocturnal creature living a solitary life and inhabit in dense forests, small vegetations, gardens, agricultural fields, plantations and ceilings of buildings.

Pathogens and pathological conditions associated with this species are poorly documented. Given the potential for transmission of diseases between them, humans and domestic animals, the present case is documented. Susceptibility

of this species to a number of zoonotic pathogens including SARS corona virus (Guan *et al.*, 2003), rabies (Mastumoto *et al.*, 2011) and highly pathogenic avian influenza H5N1 (Robertson *et al.*, 2006) has been documented earlier. In this present communication, we report an outbreak of canine distemper in Asian palm civet which caused mass mortality in three areas of Thiruvananthapuram district, Kerala during the month of April, 2020.

### **CASE HISTORY AND OBSERVATION**

About twenty palm civets died in the month of April in three different localities of Thiruvananthapuram district, Kerala. Clinical symptoms were mostly unnoticed and reports of carcasses being found in fields and near human households prompted the Animal Disease Control Wing, Thiruvananthapuram of Animal Husbandry Department, Kerala for investigating the deaths. As the time of the outbreak coincided with the COVID-19 epidemic in humans and national lockdown imposed by the government, it brought panic among public, media attention and curiosity among public health specialists. A total of five fresh carcasses representing three areas were brought to the State Institute for Animal Diseases, Palode for detailed post mortem examination. Gross pathological lesions were similar in all the carcasses revealing

pneumonia, gastroenteritis and meningitis. Samples were collected for laboratory investigations including histopathological and microbiological examinations. As epidemiological observations of rapid spread, mass mortality and pathological lesions suggested distemper like infectious disease, samples were tested for canine distemper by commercially available canine distemper virus (CDV) antigen test kits (M/s Bionote, Korea) and were positive (Fig. 1). Histopathological examination revealed pneumonia (Fig. 2), submucosal haemorrhage, mononuclear infiltration in stomach and intestine (Fig. 3) and nonsuppurative encephalitis. Characteristic intracytoplasmic inclusions were present in bronchial epithelial cells. Various other laboratory investigations conducted *viz.* bacteriological culture; antigen detection tests for rabies, canine parvo viral enteritis, canine corona viral enteritis, feline corona infection and feline panleukopenia were found to be negative. Based on the pathologic manifestations, test results and literature review (Techangamsuwan *et al.*, 2014; Wicker *et al.*, 2016), CDV was considered as the etiology of disease outbreak. Timely diagnosis could alleviate the anxiety of public and administrators.

### **DISCUSSION**

Canine distemper epidemics are common in domestic dog population and

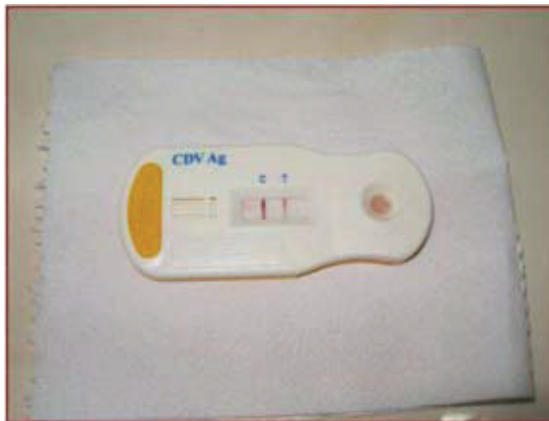

Fig 1: Rapid Immuno chromatographic Assay for CDV Antigen

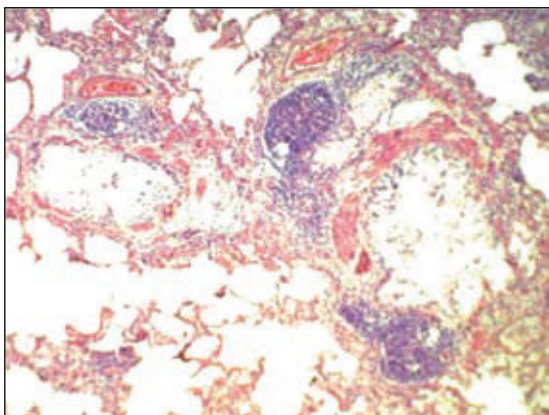


Fig 2: Section of pneumonic Lungs, 200X, H&E

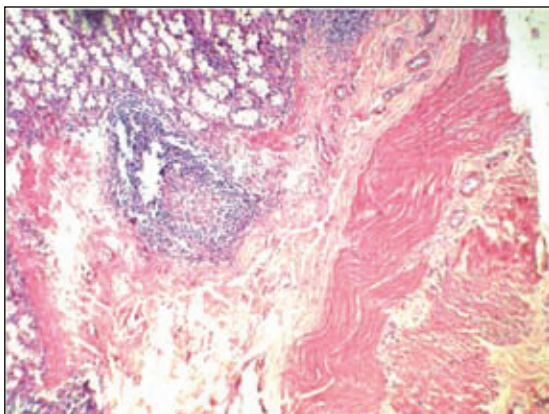


Fig 3: Section of intestine showing sub mucosal infiltration and hemorrhage, 400X, H&E

are not uncommon in captive zoo large felines and wild animals (Appel *et al.*, 1994; He Zhang *et al.*, 2017). Recently, CDV has expanded its host range into species that

are evolutionarily distinct from canines (Baumgartner *et al.*, 2003) as the one reported in this communication. Possible source of infection in this present outbreak could be direct contact with infected dogs or indirect contact with virus contaminated objects. The virus also spreads through aerosol droplets and contact with secretions of infected animals. These infected animals could pose a serious threat to the health of pets, zoo animals and wild animals in the areas they inhabit. Even though effective CDV vaccine are available for dogs, due to high cost and short protection period, vaccinations are not routinely carried out in field and hence immunological coverage is poor. The report highlights the importance of routine immunization in domesticated dogs and ensuring bio-security for domesticated pets. In India, where canine distemper is considered endemic in dogs, there are only limited studies of cross species infections. Cross species transmission can lead to deleterious effects in incidental hosts (Mendenhall *et al.*, 2016) as CDV has been described as an agent looking for new hosts (Baumgartner *et al.*, 2003).

Pathological lesions and laboratory findings typically resembled distemper infection (Appel *et al.*, 1994). Investigation in the present case is undoubtedly incomplete without molecular confirmation and characterization. However, it

merits reporting considering the health implications in animals and scarcity of documented reports of potential pathogens in civet cats which is a common animal in human habitats of India. It is of concern given the anthropogenic factors that bring humans and domestic animals into close contact with viverrids, facilitating transmission and spill over of organisms between species.

### SUMMARY

An outbreak of canine distemper in Palm civets is reported highlighting the vulnerability of wildlife to common infectious agents and the possibility of transmitting the same to companion animals and vice versa.

**Ethics statement:** This study does not involve animal experimentation and was conducted on cases reported in the hospitals, following standard operating protocols of animal handling and sample examination, upon informed consent of owners.

### REFERENCES

- Appel, M.J., Yates, R.A and Foley, G.L. 1994. Canine distemper epizootic in lions, tigers and leopards in North America. *J. Vet. Diag. Invest.* **6**(3): 277-288.
- Baumgärtner, W., Alldinger, S., Beineke, A., Gröters, S., Herden, C., Kaim, U., Müller, G., Seeliger, F., Van Moll Pa and Wohlsein, P. 2003. Canine Distemper Virus- An Agent Looking for New Hosts. *Dtsch. Tierarztl. Wochenschr.* **110**(4): 137-42.
- Guan, Y., Zheng, B.J., He, Y.Q., Liu, X.L., Zhuang, Z.X., Cheung, C.L., Luo, S.W., Li, P.H., Zhang, L.J., Guan, K.M., Butt, K.L., Wong, K.W., Chan, W., Lim, K.F., Shortridge, K.Y., Yuen, J.S., Peiris, M. and Poon, L.L.M. 2003. Isolation and characterisation of viruses related to the SARS coronavirus from animals in southern China. *Science*, **302**: 276– 278.
- He Zhang, Fen Shan, Xia Zhou, Bing Li, Jun-Qiong Zhai, Shu-Zhan Zou, Meng-Fan Wu, Wu Chen, Shao-Lun Zhai and Man-Lin Luo 2017. Outbreak and genotyping of canine distemper virus in captive Siberian tigers and red pandas. *Sci. Rep.* **7**: 8132.
- Matsumoto, T. K., Ahmed, O., Wimalaratne, S., Nanayakkara, D., Perera, D., Karunanayake, and Nishizono, A. 2011. Novel sylvatic rabies virus variant in endangered Golden palm civet, Sri Lanka. *Emerg. Infect. Dis.* **17**: 2346– 2349.
- Mendenhall, I.H., Low, D., Neves,

- E.S., Anwar, A., Oh, S., Su, Y.C.F., Smith, G.J.D. 2016. Evidence of canine parvovirus transmission to a civet cat (*Paradoxurus musangus*) in Singapore. *One Health*. **30** (2): 122-125.
- Roberton, S.I., Bell, D.J., Smith, G.J.D., Nicholls, J.M., Chan, K.H., Nguyen, D.T., Tran, P.Q., Stericher, U., Poon, L.L.M., Chen, H., Horby, P., Guardo, M., Guan, Y. and Peiris, J.S.M. 2006. Avian influenza H5N1 in viverrids: implications for wildlife health and conservation. *Proc. R. Soc. B*. **273**: 1729– 1732.
- Techangamsuwan, S., Banlunara, W., Radtanakatikanon, A., Sommanustweechai, A., Siriaroonrat, B., Lombardini, E. D. and Rungsipipat, A. 2014. Pathologic and Molecular Virologic Characterization of a Canine Distemper Outbreak in Farmed Civets. *Vet. Pathol.* 1-8.
- Wicker, L. V., Canfield, P. J. and Higgin D. P (2016). Potential Pathogens Reported in Species of the Family Viverridae and Their Implications for Human and Animal Health. *Zoonoses Public Health* **64** (2): 75-93.





---

## SURGICAL CORRECTION OF PERSISTENT URACHUS AND IMPERFORATE URETHRA IN A TWO-DAY-OLD CROSS BRED JERSEY CALF

Sherin B. Sarangom<sup>1\*</sup>, Kiran Viswanath<sup>2</sup>, Seeja Sundaran<sup>1</sup>, Preena P.<sup>1</sup>, Varsha Mary Mathai<sup>3</sup> and Muraleedharan K.<sup>4</sup>

<sup>1</sup>Veterinary Surgeon, District Veterinary Centre, Kannur; <sup>2</sup>Veterinary Surgeon, Veterinary Dispensary, Kadambur, Kannur; <sup>3</sup>Veterinary Surgeon, Emergency Veterinary Services, Veterinary Polyclinic, Taliparamba, Kannur; <sup>4</sup>Senior Veterinary Surgeon, District Veterinary Centre, Kannur, Kerala, India  
\*Corresponding author: sbs04vet@gmail.com

---

### ABSTRACT

A two-day-old female cross bred Jersey calf was presented with history of dribbling of urine through the umbilicus, but not passing urine through the natural urethral opening since birth. The condition was diagnosed as persistent urachus and congenital imperforate urethra based on the history, clinical signs, radiographic and ultrasonographic findings. Under general anaesthesia, the stalk of persistent urachus was identified, carefully ligated and separated through a ventral mid-line laparotomy. The patency of the external urethra was accomplished by gentle digital pressure. The animal had an uneventful recovery.

**Keywords:** Patent urachus, Persistent urachus, Imperforate urethra, Umbilicus

### INTRODUCTION

Persistent urachus is a congenital defect where a functional foetal urachus, which communicated the urinary bladder with the allantois during the prenatal life, failed completely to get atrophied and cicatrized even after birth (Osborne *et al.*, 1987). Neonatal omphalitis, umbilical abscess and congenital urethral obstruction might also lead to the development of this condition (Mc Gavin *et al.*, 2001). The condition occurred commonly in foals, but was infrequently reported in calves (Fazili *et al.*, 1998; Mendoza *et al.*, 2010). Persistent urachus occurred either alone; or in association with urethral obstruction or other congenital abnormalities (Nikahval and Khafi, 2013; Nair *et al.*, 2017). The condition was usually accompanied by complications such as omphalitis, rupture

of urachus and uroperitoneum (Hylton and Trent, 1987; Braun *et al.*, 2009; Mendoza *et al.*, 2010); and immediate treatment if not attempted might deteriorate the condition of the animal, develop potential complications and could be life threatening. The present case, reports the diagnosis and successful surgical management of persistent urachus and congenital imperforate urethra in a two-day-old female cross bred Jersey calf.

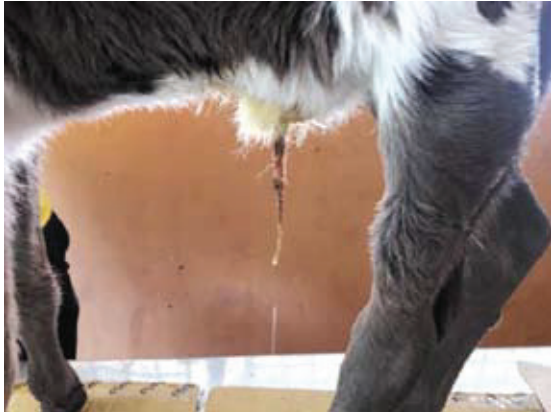
#### **CASE HISTORY AND OBSERVATION**

A two-day-old female cross bred Jersey calf was presented to the outpatient unit with the history of not passing urine through natural urethral opening but draining through the umbilicus since birth (Fig. 1). On clinical examination, the animal appeared active and alert. Frequent leakage of urine through the umbilicus was observed along with mild omphalitis. Catheterisation of the umbilical opening revealed the presence of a tubular tunnel along with leakage of urine through the catheter when progressed anteriorly. Radiographic examination of the abdomen in orthogonal views after catheterisation through the umbilical orifice confirmed the presence of the metallic catheter within the urinary bladder which entered through its caudo-ventral border (Fig. 2A). Abdominal ultrasonographic examination (3-5 MHz convex transducer, Mindray Bio-Medical Electronics Co., Ltd., Shenzhen, China)

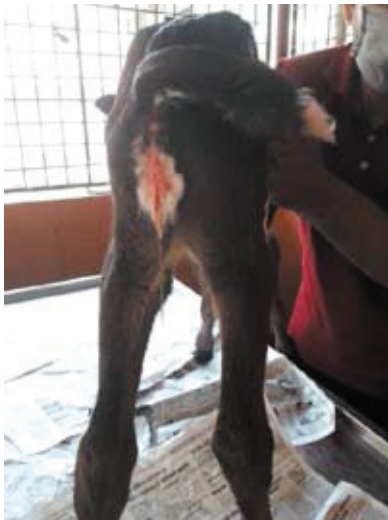showed normal urinary bladder margins and reverberation within due to the metallic catheter (Fig. 2B). At the other end, a probing catheter could not be progressed beyond the external urethral orifice. Based on the history, clinical signs, radiographic and ultrasonographic findings, the condition was diagnosed as patent urachus and congenital imperforate urethra. The haematological and serological parameters were normal. Hence, surgical correction was resorted to.

#### **TREATMENT AND DISCUSSION**

The calf was fasted six hours prior to surgery. Pre-operatively, Ceftriaxone sodium (Intacef pet, Intas Pharmaceuticals Ltd., Ahmedabad) at the rate of 25 mg/kg body weight, meloxicam (Melonex, Intas Pharmaceuticals Ltd., Ahmedabad) at the rate of 0.3 mg/kg body weight and butorphanol (Butrum-1, Aristo Pharmaceuticals Pvt. Ltd., Raisen) at the rate of 0.05 mg/kg body weight were administered intravenously. The ventral abdomen extending from the xiphoid to the pubis was clipped, shaved and scrubbed with one per cent chlorhexidine solution. General anaesthesia was induced with intramuscular injection of ketamine hydrochloride (Aneket, Neon Laboratories Ltd., Mumbai) administered at the rate of 3 mg/kg body weight followed by diazepam (Calmpose, Ranbaxy laboratories Ltd.,

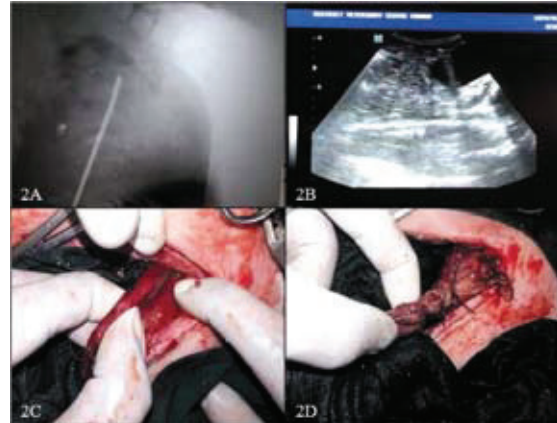


**Fig. 1.** The calf presented with dribbling of urine through the umbilicus



**Fig. 3.** The calf voiding urine normally during the immediate postoperative period

Baddi) at the rate of 0.2 mg/kg body weight intravenously. Anaesthesia was maintained with a mixture of ketamine hydrochloride and diazepam (1:1 v/v) along with intravenous infusion of normal saline. Local analgesia was achieved by infiltration of two per cent lignocaine hydrochloride solution (Xylocaine two per cent, Astra Zeneca Pharma India Ltd., Dundigal) around the umbilicus.



**Fig. 2.** Lateral abdominal radiograph showing presence of metallic catheter within the urinary bladder with the entry point at the caudo-ventral border (A). The normal bladder margin and reverberation due to the metallic catheter observed in diagnostic ultrasound (B). The patent urachal cord with attachment on the caudo-ventral border of urinary bladder (C) and the stalk double ligated close to the bladder wall (D).

A standard mid-ventral approach was taken for the repair. The calf was positioned in dorsal recumbency and the surgical site was aseptically prepared with povidone iodine (5 per cent) solution and was draped. A 10 cm long elliptical incision was made around the umbilicus extending caudally along the ventral midline region towards the pubis. The incision was deepened along the *linea alba* to enter the peritoneal cavity. The cord of the pervious urachus was identified. The cord was used to trace the stalk that attached the caudo-ventral border of urinary bladder (Fig. 2C). The stalk of the pervious urachus was double ligated close to the bladder using No. 1 Polyglactin 910 (Vicryl, Johnson and Johnson Ltd., Aurangabad, India) and was resected (Fig. 2D). The stump

of the cord was apposed by purse string suture pattern using No. 2-0 Polyglactin 910. The resected urachus along with the umbilical cord were bluntly separated and removed. The abdominal cavity was meticulously explored to rule out any concurrent abnormalities and presence of adhesions. The mucosal adhesion on the external urethral orifice was separated by gentle digital pressure and the patency of urethra was confirmed with the help of a urinary catheter. The abdominal cavity was lavaged with sterile normal saline solution (0.9 per cent). The *linea alba* was apposed in simple continuous suture pattern using No. 1 Polyglactin 910. The skin wound was closed in simple interrupted suture pattern using No. 1 polyamide (Trulon, Sutures India Pvt. Ltd., Bangalore, India). The calf started voiding urine through the external urethral orifice normally during the immediate postoperative period (Fig. 3). Postoperatively, antibiotics (ceftriaxone sodium) were continued for five more days and analgesics (meloxicam) for three more days. Antiseptic wound dressing was done regularly using 5 per cent povidone iodine solution and the skin sutures were removed on the 12<sup>th</sup> postoperative day. Postoperative complications were not observed and the animal had an uneventful recovery.

The history and clinical signs in the present case were similar to that reported previously. Dribbling of urine

through the umbilicus, the consistent sign previously reported by Nikahval and Khafi (2013) and Nair *et al.* (2017), was observed in the present case also. Usually, the pervious urachus may be accompanied by omphalitis, rupture of urachus and uroperitoneum and may subsequently lead to cystitis, urachitis, urinary incontinence, peritonitis and urine scalding during the time of presentation (Hylton and Trent, 1987; Braun *et al.*, 2009; Mendoza *et al.*, 2010; Nikahval and Khafi, 2013; Nair *et al.*, 2017). Such complications were not observed in the present case. Radiography and diagnostic ultrasound assisted in assessing the patency of the urachus, ruling out potential complications and in making a definitive diagnosis. Also, the normal physiological and haemato-biochemical parameters indicated non-existence of any concurrent systemic illness. But, the urachus was accompanied by the presence of urethral obstruction due to a membranous diaphragm occluding the external urethral meatus as reported by Hylton and Trent (1987). Congenital urethral stricture and other congenital anomalies have also been reported (Nikahval and Khafi, 2013; Nair *et al.*, 2017). Although topical application of intra-urachal cauterizing agents is a treatment option for patent urachus, surgical ligation and removal of umbilical remnants were attempted to avoid ascending infection to the intra-abdominal

structures through leakage of urine from intra-abdominal umbilical remnants or by rupture of urachus (Baird, 2008; Braun *et al.*, 2009; Mendoza *et al.*, 2010; Grover and Godden, 2011).

The animal recovered uneventfully without any postoperative complications and the successful outcome could be attributed to the early presentation, good body condition, absence of any concurrent anomalies or systemic illness, presence of an intact urinary bladder and urachus, careful ligation and removal of umbilical remnant close to the bladder without any spillage of urine into the abdominal cavity, meticulous postoperative care and the concern of the owner.

#### SUMMARY

The diagnosis and successful surgical management of persistent patent urachus and congenital imperforate urethra in a two-day-old female cross bred Jersey calf is discussed.

#### ACKNOWLEDGEMENT

The authors are thankful to the Director, Animal Husbandry Department, Kerala and the District Animal Husbandry Officer, Kannur, Kerala for providing facilities for the study.

**Ethics statement:** This study does not involve animal experimentation and was

conducted on cases reported in the hospitals, following standard operating protocols of animal handling and sample examination, upon informed consent of owners.

#### REFERENCES

- Baird, A.N. 2008. Umbilical surgery in calves. *Vet. Clin. North Am. Food Anim. Pract.* **24**(3): 467-477.
- Braun, U., Previtali, M., Furst, A., Wehrli, M. and Muggli, E. 2009. Cystoscopy in a heifer with rupture of a patent urachus. *Schweiz. Arch. Tierheilkd.* **151**(11): 539-543.
- Fazili, M.R., Peer, F., Masoodi, A.H. and Ahmad, M.M. 1998. Surgical management of pervious urachus in two calves. *Indian. J. Vet. Surg.* **19**(2): 127.
- Grover, W.M. and Godden, S. 2011. Efficacy of a new navel dip to prevent umbilical infection in dairy calves. *Bovine Pract.* **45**(1): 70-77.
- Hylton, W. and Trent, A.M. 1987. Congenital urethral obstruction, uroperitoneum, and omphalitis in a calf. *J. Am. Vet. Med. Assoc.* **190**(4): 433-434.
- Mendoza, F., Lopez, M., Diez, E., Perez-Ecija, A. and Estepa, J. 2010. Uroperitoneum secondary to



- rupture of the urachus associated with *Clostridium* spp. infection in a foal: a case report. *Vet. Med.* **55**(8): 399-404.
- Mc Gavin, M.D., Carlton, W.W. and Zachary, J.F. 2001. The urinary system. In: *Thomson's Special Veterinary Pathology*, 3<sup>rd</sup> Ed., Mosby, Philadelphia. 768 p.
- Nair, S.S., Devanand, C.B., Anoop, S. and Kumar, H.H.V. 2017. Surgical management of patent urachus and congenital urethral stricture in a calf: A case report. *Indian Vet. J.* **94**(9): 49-50.
- Nikahval, B. and Khafi, M.S.A. 2013. Congenital persistent urachus, urethral obstruction and uroperitoneum in a calf. *Iranian J. Vet. Res.* **14**(2): 158-160.
- Osborne, C.A., Johnston, G.R., Kruger, J.M., O'Brien, T.D. and Lulich, J.P. 1987. Etiopathogenesis and biological behavior of feline vesicourachal diverticula. *Vet. Clin. North Am. Small Anim. Pract.* **17**(3): 697-733.
-

---

## MANAGEMENT OF SUPERFICIAL WOUNDS IN A CAPTIVE ASIAN ELEPHANT WITH BISMUTH IODOFORM PARAFFIN PASTE AND ZINC OXIDE OINTMENT

Rajeev T.S<sup>1\*</sup>, Vysakh Viswam<sup>2</sup> and Anoop S<sup>3</sup>.

<sup>1</sup>Associate Professor, Department of Animal Husbandry Extension,

<sup>2</sup>Teaching Assistant, University Pig Breeding and Research Station,

<sup>3</sup>Associate Professor, Department of Surgery and Radiology

College of Veterinary and Animal Sciences, Mannuthy, Trichur, Kerala-680651

\* Corresponding author: [rajeev@kvasu.ac.in](mailto:rajeev@kvasu.ac.in)

---

### ABSTRACT

Superficial skin wounds are very common in captive Asian elephants which continues to be a challenge for practicing veterinarians, as it is difficult to manage these wounds. A variety of reasons are attributed to the development of wounds in elephants including those associated with chains, mahout induced, self-inflicted trauma and various types of trauma during accidents. The use of bismuth iodoform paraffin paste (BIPP) and zinc oxide ointment in the management of multiple wounds and wound mapping to assess the progress of healing are described.

**Keywords:** Asian elephant, BIPP, Superficial wound, Zinc oxide, Wound mapping

### INTRODUCTION

The elephants reared in captivity for

public performances in Kerala are usually controlled and managed using metallic hobbles, chains and associated equipments. Such harnessing measures make the pachyderms highly prone to superficial open and closed traumatic wounds. Besides, they encounter several other traumatic injuries resulting in a variety of superficial and deep wounds. The skin of Asian elephant (*Elephas maximus*) is very thick measuring about 2.5-5.0 cm (Sukklad *et al.*, 2006) with loosely attached facia leading to reduced circulation peripherally and also lacks sebaceous glands. These anatomical factors may interfere with normal wound healing in elephants (Sukumar, 2003). In wild, they are capacitated to make use of mud and slush to cover skin for the retention of moisture and protection from sun light. In general, various types of wounds may occur in all parts of the body in elephants and may become chronic or

ulcerated, if not attended on time (Courtois *et al.*, 2003). Latent period of ulceration may vary from weeks to months (Schmidt, 1986). Tuskers in captivity has to undergo prolonged chaining and associated control during the entire period of musth leading to various types of wounds induced by chain and other restraining devices used in limbs and self-inflicted injuries by the animal as part of their behavioral changes during musth. The epidermis, dermis and adjacent superficial keratinized stratified layers of the skin, may undergo erosion and exfoliation exposing the deeper layers of the skin, resulting in a wound. This type of wounds always remains as a challenge for the owner, mahout and veterinarian as it is difficult to approach and give proper care to the wound as the animal is in musth.

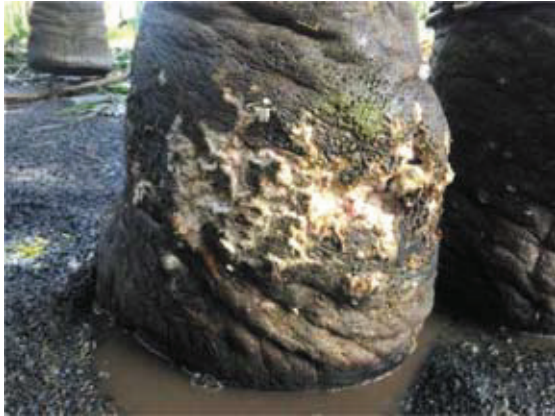### **CASE HISTORY AND OBSERVATIONS**

A 37-year-old captive Asian male elephant was reported to have multiple chain wounds which developed on the hind limbs during the musth period. At the time of examination, the elephant was in post musth period and mahouts were advised to release the elephant from restraints. Physical examination of the wound revealed multiple large sized irregular superficial wounds on the lateral palmar aspect of the fetlock joints of both hind limbs (Fig.1).

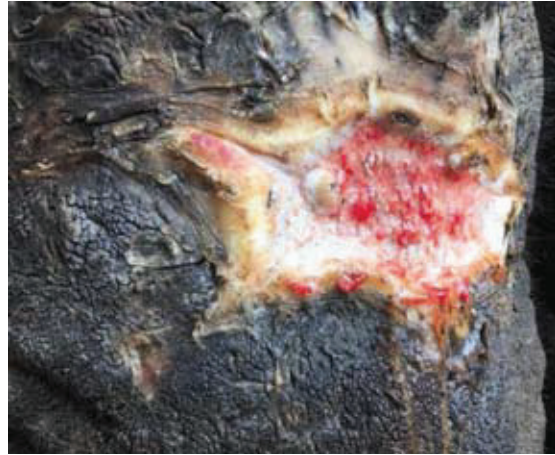### **TREATMENT AND DISCUSSION**

As the wounds were contaminated with mud and bedding materials, the wounds were cleansed by normal saline lavage. Detailed examination revealed involvement of epidermis and dermis and pus discharge from the wound. The outline of the wounds was mapped using a marker and polythene sheet placed over the wounds to assess the progression of wound healing. The wounds were then thoroughly lavaged with hydrogen peroxide solution (3 per cent) to remove the pus and other necrotic tissues. Potassium permanganate solution (1 in 1000) was also used to clean the wound edges. The whole wound was then painted with Tincture iodine solution. A gauze seaton was dipped in tincture iodine solution and kept over the wound bed to increase the contact time of the medicine.

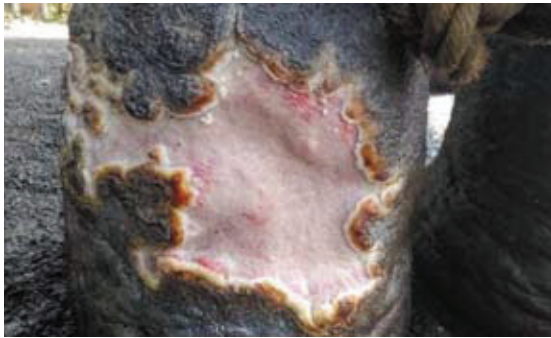From day 6, the healthy granulation tissue started appearing with complete reduction of the necrotic tissue and pus discharge. Bismuth iodoform paraffin paste (BIPP) was advised for topical use in the wounds till a healthy granulation bed appeared. The treatment with BIPP was continued for one month and the tissue bed became organized and healthy, with complete healing of dermis and epidermis (Fig. 2-5) The treatment protocol was changed and Zinc oxide cream (Zinc



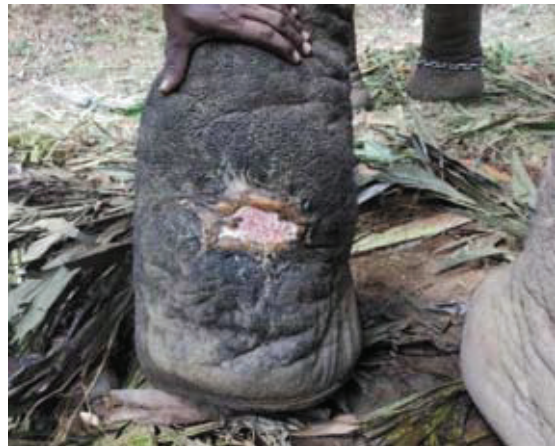**Fig. 1.** Wound on the hind limb



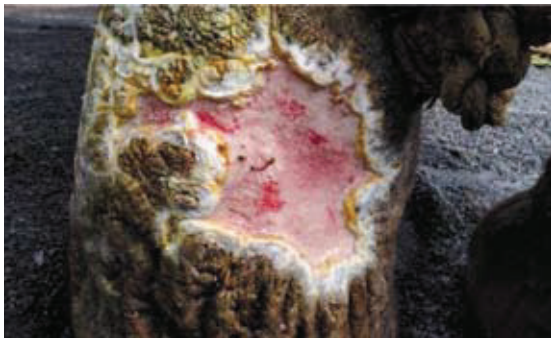**Fig. 4.** Day 90



**Fig. 2.** Day 21



**Fig. 5.** Day 120



**Fig. 3.** Day 50

oxide powder 10 per cent w/w and white soft paraffin 90 per cent w/w.) was advised to promote epithelialization and keratinization. On day 150, there was considerable reduction on size of the wound margins and there was complete healing of the wound with complete epithelialization

leaving only a scar at the wound site.

Wound mapping, a procedure for pictorial representation of the wound is represented in Fig. 6. It was manually done by tracing the outline of the wound margin on to a transparent acetate sheets and the surface area estimated. In wounds that are approximately circular, the longest diameter in one plane was multiplied by the longest diameter in the plane at right angles; in irregularly shaped wounds, add up the number of squares contained within






Fig. 6. Wound mapping (Day 1, 120)

the margin of the outline of the wound from an acetate grid tracing. Finally, the area calculated in the final mapping is compared with the value obtained in the first mapping. These methods are the simplest, but it should be recognised that they are not precise. However, they do provide a means by which progress over time to wound closure can be identified. Patient positioning, body curvature, or tapering of the limbs will affect the accuracy of these techniques. Wound mapping which can be done either manually or with software is a valuable tool to assess the progress of wound healing.

Bismuth iodofom paraffin paste is an agent used since ages in medical practice for suppurating wounds of superficial character (Morrison, 1916). Composition of BIPP is iodoform BP 40 per cent w/w and bismuth subnitrate BP 20 per cent w/w, white soft paraffin 40 per cent w/w. A paste is available presented in a labelled aluminium

laminated pouch. Hypersensitivity to iodine can result in an erythematous rash which usually subsides on cessation of the application.

#### SUMMARY

In the present study as there was reduction in the wound surface area and complete epithelialization with application of BIPP and Zinc oxide cream, it can be concluded that this combination is effective in managing the superficial skin wounds in elephants. This can also be recommended for many of the superficial skin wounds of elephants keeping in mind the stage of wound healing, nature of wound and the other environmental factors.

**Ethics statement:** This study does not involve animal experimentation and was conducted on cases reported in the hospitals, following standard operating protocols of animal handling and sample examination, upon informed consent of owners.



**REFERENCES**

- Fowler, M.E and Mikota, S. 2006. *Medicine and Surgery of elephants*. (1<sup>st</sup> Ed.). Blackwell Publishers, USA, 565p.
- Courtois, O.F., Lecu, A., Yates, R.A and Spelman, L.H. 2003. Treatment of a sole abscess in an Asian elephant (*Elephas maximus*) using regional digital intravenous perfusion. *J. Zoo Wildlife Med.* **34**: 292-295.
- Morrison R. 1916. The treatment of infected suppurating war wounds. *Lancet*, **ii**:268-272.
- Schmidt, M. 1986. In: Murray and Fowler (ed), *Elephants in Zoo and wild Animal Medicine*. (2<sup>nd</sup> Ed), WB Saunders Company, Philadelphia, 908p.
- Sukklad, S., Sommanustweechai, A. and Pattanarangsarn. 2006. A retrospective study of elephant wound, wound management from Thai veterinarians. In: *Proceedings of AZWMP*. October 26-29, Bangkok, Thailand, 16p.
- Sukumar, R. 2003. *The Living Elephants: Evolutionary Ecology, Behavior, and Conservation*. (1<sup>st</sup> Ed.), Oxford University Press, USA, 149p.
-

---

## A CASE REPORT ON CHRONIC RENAL FAILURE DUE TO OCCULT BABESIOSIS IN A DOG

Shyma V.H.\* , Anugraha Mercy Easaw and Vijayakumar K.

*Department of Veterinary Epidemiology and Preventive Medicine College of Veterinary and Animal Sciences, Mannuthy, Thrissur, Kerala, India*

*\*Corresponding author: shymavh@gmail.com*

---

### ABSTRACT

A three-year-old Saint Bernard was presented with history of chronic gastro intestinal disorder, with progressively elevating creatinine values and without any response to treatment. Molecular detection by polymerase chain reaction aided in diagnosis of the condition as chronic canine babesiosis with Multi Organ Dysfunction (MODS). Animal responded to treatment for *Babesia gibsoni* infection with Clindamycin and Doxycycline parenterally in the initial stages but succumbed to the infection later. The present paper describes a case of *B. gibsoni* infection leading to Chronic Kidney Disease (CKD) and its sequelae.

**Key words:** *B. gibsoni*, multi organ dysfunction, chronic kidney disease

### INTRODUCTION

Canine babesiosis is a tickborne disease which is caused by intraerythrocytic

haemoprotozoa. The most commonly encountered species in dogs include *B. canis* and *B. gibsoni*. It can be exhibited as complicated or uncomplicated cases depending on the clinical manifestations. Uncomplicated babesiosis leads to anemia resulting from haemolysis whereas manifestations in complicated babesiosis are variable. This is attributed to cytokine induced phenomenon which leads to multiorgan dysfunction and systemic inflammatory response syndrome (SIRS). According to Lobetti *et al.*(1996), the insult to kidneys resulted in acute renal injury due to anaemic hypoxia, reduction in renal blood flow, and hypotension with intra-renal vasoconstriction and renal ischaemia. The exact pathogenesis attributed to kidney damage is still obscure.

### CASE HISTORY AND OBSERVATION

A three-year-old male Saint Bernard was presented to Teaching Veterinary Clinical Complex, Mannuthy

with a history of inappetence, vomiting and lethargy. The animal was being treated for more than a year for recurrent episodes of gastrointestinal disorders. It was treated with metronidazole, ceftriaxone, ivermectin, B vitamins, Lactobacillus probiotics, anti-emetics, antacids, appetite stimulants (cyproheptadine, aristozyne) and liver protective. Animal had severe anaemia with VPRC of 9.9 per cent and serum creatinine value of 7.8 mg/dl. Haemoparasites could not be identified in the peripheral blood smear examination conducted one week prior to presentation. On the day of presentation, haematological analysis revealed severe anaemia (RBC- $1.83 \times 10^6$  / $\mu$ l, Hb-3.4g/dl, HCT-9.9 per cent, MCV-54.1, MCH-18.6 $\mu$ g). Creatinine level was 11.86 mg/dl on serum biochemical examination. Blood gas analysis revealed metabolic acidosis (Bicarbonate level-11 m mol /l) and all electrolytes were within normal limits. Urine analysis was also carried out, which revealed proteinuria and lower range of specific gravity (1.015), confirming the severity of renal damage.

Supportive therapy was initiated with sodium bicarbonate 7.5 per cent 60 ml, pantoprazole 40mg, darbepoetin 0.2 ml subcutaneous and fresh blood transfusion of 570 ml on the next day to alleviate anaemia. During the consecutive days, animal had slight improvement with

VPRC elevating to 14.5 per cent, but later on reduced to 13 per cent. In addition, creatinine level increased to 16.1 mg/dl, indicating the possibility of an etiological agent causing persistent anaemia and renal injury. Even though repeated peripheral blood smear examination did not reveal any haemoparasites, due to the persistent anaemia and unresponsiveness to treatment, blood was collected for molecular detection of any blood parasite. On polymerase chain reaction, the animal was found to be positive for *B.gibsoni* and negative for *Ehrlichia canis* and *B. canis*.

#### TREATMENT AND DISCUSSION

Conservative treatment for babesiosis was initiated with Doxycycline @ 2.5 mg/kg bwt (Intravenous) and Clindamycin @ 5.5 mg/ bwt (Intravenous) avoiding all nephrotoxic drugs like imidocarb, metronidazole and buparvaquone. By second week of treatment, anaemia had improved with an elevated PCV of 16.2 per cent but creatinine values had increased to 18.32 mg/dl revealing the poor prognosis of the condition. Animal deteriorated in condition by third week and succumbed to the infection.

Renal involvement is common in complicated and uncomplicated babesiosis. It resembles as that of failure due to sepsis by common infectious agents

like brucellosis, ehrlichiosis, leptospirosis and heart worm disease. In babesiosis of dogs, chronic antigenic stimulation may lead to sequelae such as membranoproliferative glomerulonephritis with IgM deposits that has been demonstrated in experimental infection with the California isolates (Wozniak *et al.*, 1997) and has persistently elevated creatinine levels. Proteinuria is reported to be another consistent finding even though not necessarily reflecting a renal failure as observed by Lobetti and Jackson (2001). Tarini *et al.* (2018) also reported azotemia and proteinuria in dogs infected with *B. gibsoni*. Depending on the type of *Babesia* species, stage of diagnosis and treatment protocol used, the prognosis of most cases are 50-90 per cent whereas in complicated babesiosis causing SIRS and MODS, the prognosis is poor. Mortality can reach upto 50 - 100 per cent, despite intensive, technically advanced interventions in such cases (Welzl *et al.*, 2001).

## SUMMARY

Early detection of SIRS and MODS is of major importance in clinical practice for providing insight about severity and outcome of the disease and therapy. The presented case showed the importance of early detection of the primary cause of kidney injury in young animals for a favorable prognosis. Molecular detection

plays a vital role in finding etiological agent when conventional methods do not aid in a confirmatory diagnosis. The presented case described chronic babesiosis in dogs, leading to irreversible kidney damage.

**Ethics statement:** This study does not involve animal experimentation and was conducted on cases reported in the hospitals, following standard operating protocols of animal handling and sample examination, upon informed consent of owners.

## REFERENCES

- Lobetti, R.G., Reyers, F. and Nesbit, J.W. 1996. The comparative role of haemoglobinaemia and hypoxia in the development of canine babesial nephropathy. *J. S. Afr. Vet. Assoc.* **67**(4): 188-198.
- Lobetti, R. G. and Jacobson, L.S. 2001. Renal involvement in dogs with babesiosis. *J. S. Afr. Vet. Assoc.* **72**(1): 23-28.
- Tarini U., Adam B. and Shelly V. 2018. Azotemia and proteinuria in dogs infected with *Babesia gibsoni*. *J. Am. Anim. Hosp. Assoc.* **54**(3): 156-160.
- Welzl, C., Leisewitz, A.L., Jacobson, L.S., Vaughan-Scott, T. and Myburgh, E. 2001. Systemic inflammatory response syndrome and multiple-organ damage/dysfunction in

complicated canine babesiosis. *J. S. Afr. Vet. Assoc.* **72**(3): 158-162.

Wozniak, E. J., Barr, B.C., Thomford, J. W., Yamanae, I., McDonough, S.P., Moore, P.F., Naydan, D., Robinson, T. W. and Conrad, P. A. 1997. Clinical,

anatomic and immunopathologic characterisation of *Babesia gibsoni* infection in domestic dog. *J. Parasitol.* **83**: 692-699.





---

## SURGICAL MANAGEMENT OF UMBILICAL HERNIA CONCOMITANT WITH GASTROINTESTINAL FISTULA IN CALVES – REPORT OF TWO CASES

Faslu Rahman C.K.<sup>1\*</sup>, Nithin C.J.<sup>2</sup>, Arun P.<sup>3</sup>, Sharun Khan<sup>4</sup> and  
Seesma Subramaniyan<sup>5</sup>

<sup>1</sup>Division of Livestock Products Technology, ICAR- Indian Veterinary Research Institute, Izatnagar. <sup>2</sup>Veterinary surgeon, Veterinary dispensary, Maikavu, Kozhikode, <sup>3</sup>Veterinary surgeon, District Veterinary Centre, Kozhikode, <sup>4</sup>Division of veterinary surgery, ICAR- Indian Veterinary Research Institute, Izatnagar, <sup>5</sup>Department of Veterinary Surgery & Radiology, College of Veterinary and Animal Sciences, Pookode.  
\*Corresponding author: ckfashurahman@gmail.com

---

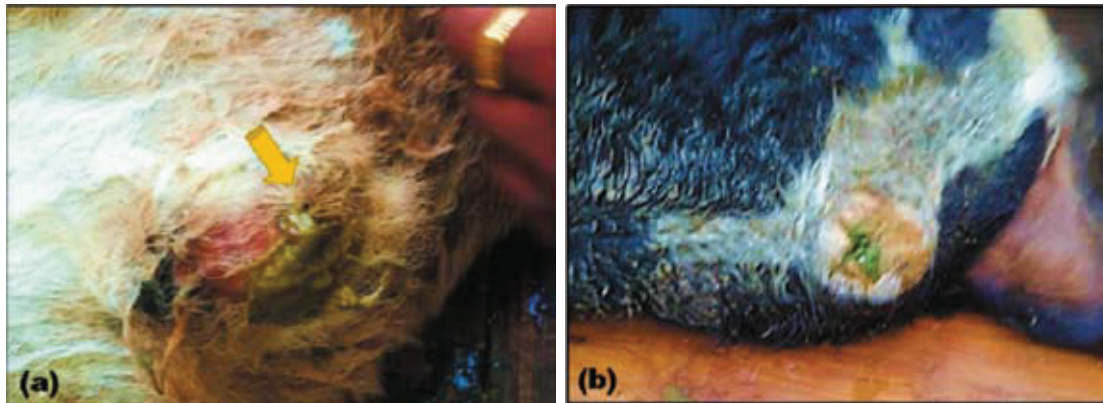
### ABSTRACT

Umbilical hernias are one of the most commonly encountered congenital defects in calves. Etiology of the defect can be improper closure of umbilical opening, hypoplasia, or maldevelopment of the abdominal musculature. Defect in mid-ventral line due to failure of closure of umbilical opening at an early embryonic stage could lead to congenital umbilical hernia. Abdominal viscera can pass through this large opening, which leads to further complications. This article reports two cases of umbilical hernia in calves, one with a complication of abomasal tear and other with intestinal tear evidenced by oozing of gastrointestinal contents through the umbilical orifice.

**Keywords** : Umbilical hernia, Calves  
Herniorraphy

### INTRODUCTION

Hernia is a condition in which part of the organ of abdomen or pelvis, either protruded or displaced with the intact peritoneal layer, through a natural or pathogenic weak opening in the thoracic or abdominal cavity containing it, with intact skin. Omphalocele (umbilical hernia) is the displacement of part of organ or complete organ through a defect in the abdominal wall at the region of umbilicus with intact skin (Doijode, 2019). Congenital umbilical hernias are common defects in calves, particularly in Holstein Friesian cattle where frequencies between 4-15 per cent have been observed (Hondele, 1986; Müller *et al.*, 1988; Virtala *et al.*, 1996). A genetic predisposition for this condition in cattle has been proposed (Ron *et al.*, 2004). Excess traction of an oversized foetus during dystocia or cutting the



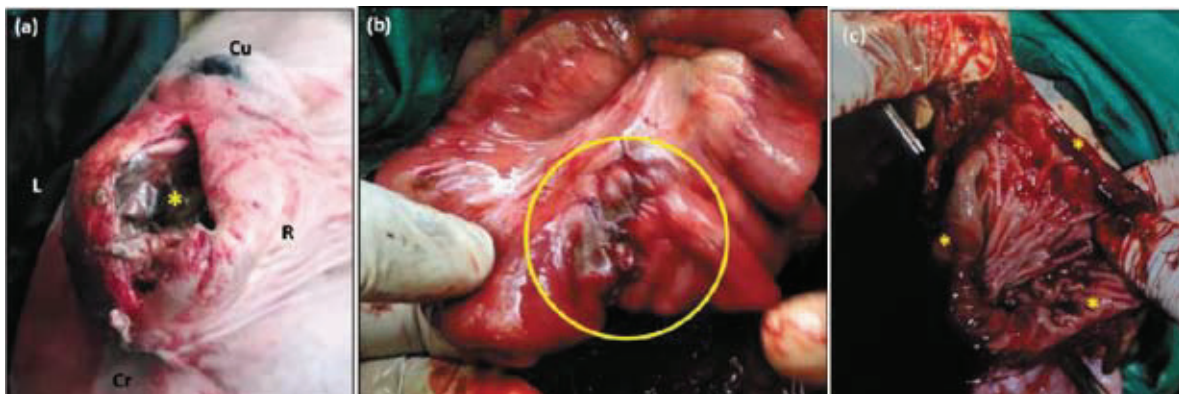**Fig. 1:** Umbilical swelling with oozing out of digesta (a) shown by arrow (case 1.) (b) Case 2.

umbilical cord too close to the abdominal wall are other possible causes (Sutradhar *et al.*, 2009). Simple umbilical hernias are non-painful and reducible when palpated (Baird, 2008). However, hernias are sometimes accompanied by severe pain, which worsens during bowel movements, urination, or straining (Bendavid *et al.*, 2001). Occasionally, a hernia can become strangulated, which occurs when the protruding tissue swells and becomes incarcerated. Strangulation will interrupt blood supply and can lead to infection, necrosis, and potentially life-threatening

conditions (Heniford, 2015). The surgical management of hernia could be done either by primary repair (herniorraphy), mesh repair (hernioplasty) or laparoscopic correction (Demirkiran *et al.*, 2003). The present paper reports two cases of umbilical hernia concomitant with gastrointestinal fistula in calves.

### CASE HISTORY AND OBSERVATION

A 3-month-old Jersey crossbred male calf and a 4-month-old crossbred Holstein Friesian male calf were presented with a complaint of oozing out of digesta



**Fig. 2** (a) Opened umbilical swelling in case 1, presence of digesta oozed out (\*), Cu- caudal, Cr- cranial, L-left, R-right. (b) Tear on intestinal loop shown in circle. (c) Abomasal tear in case 2, edges of wound could be visualized.

through the umbilical orifice with a bulging in umbilical region (Fig.1a,b). On general clinical examination, animals were found to be normal except for distended abdomen. The physiological parameters were found to be within the normal range. On palpation of umbilical mass, the hernial ring could be felt. Based on the history and clinical examination, the case was tentatively diagnosed as the umbilical hernia with a complication of digestive tract rupture. For further confirmation, it was decided to perform exploratory laparotomy to identify the point of rupture and to take corrective action.

#### **TREATMENT AND DISCUSSION**

In both animals, umbilical area was cleaned and wiped with a clean cotton towel and cotton plugs are applied over the orifice in order to prevent the contamination of the site. The 24 hours fasted animals were administered with antibiotic Ceftiofur (Xceft™ inj.) @ dose rate of 2.2 mg/kg intramuscularly and Nonsteroidal anti-inflammatory drug (NSAID) Meloxicam (Melonex™ inj.) @ dose rate of 0.3mg/kg intramuscularly. Sedated the animal using xylazine (Xylaxin® inj.) at the dose rate of 0.05mg/kg body weight intramuscularly and ketamine at the dose rate of 3mg/kg body weight intramuscularly. Animal was positioned in dorsal decumbency in order to prepare ventral abdomen for aseptic surgery.

Elliptical local anaesthesia was performed by infiltration of Lignocaine hydrochloride (Lox®) 2 per cent @ 0.2 ml/kg body weight around umbilicus by using an 18G needle. Swollen umbilical skin was incised in a simple elliptical manner with a #22 scalpel blade with caution, to ensure adequate skin was available for skin closure after surgery. Then, the hernial sac was exposed after proceeding to the subcutaneous tissue with a Metzenbaum scissor around the mass. In the first case, it was found that the loop of the small intestine had a tear of about 5cm and the contents had being oozed out into the peritoneum and then through the umbilical orifice. The torn intestinal loop was retraced out through the wound, stay suture was applied for major mesenteric blood vessels, and the unhealthy intestinal segment was removed. Enteroanastomosis was performed by placing simple interrupted sutures using chromic catgut (size 1/0). Abdomen was lavaged with normal saline and contents were replaced into the abdominal cavity. Muscles were apposed by using Polyglycolic acid (PGA) (size 1/0) in simple continuous pattern and skin was apposed by nylon. These sutures were removed by 14 day, post-operatively.

In second case, exploratory laparotomy was conducted as previous case and found that the contents being oozed out from a puncture hole of abomasum.

Extensive abdominal lavage was performed by using normal saline. Edges of the abomasal wound were scarified and apposed by Connell's followed by Lembert's suture patterns using chromic catgut (size 1/0). The procedure is represented in Fig. 2. In both cases post-operative antibiotic care was provided and both animals recovered uneventfully.

Singh *et al.* (2006) reported that umbilical hernias were defect in abdominal wall with multi-factorial aetiology which resulted in globular swelling at the point of the umbilicus. Defect in mid-ventral line due to failure of closure of umbilical opening at early embryonic stage leads to congenital umbilical hernia. Abdominal viscera like intestine, abomasum, omentum can herniate through this large opening, leading to further complications. Baird (2016) reported that hernia and associated complications could be surgically corrected by herniorrhaphy. Here, in both cases, herniorrhaphy was performed successfully. The author also stated that incarceration of masses like intestine especially jejunum and abomasum could lead to tearing of viscus and complications as reported in the present study.

Enterocutaneous fistula could also be a reason for oozing out of digesta from abdomen in various animals (Fubini

and smith, 1984, Rijkenhuizen and Sickmann 1995). Pyloro-duodenal hernia with enterocutaneous fistula, surgically corrected by ventrolateral herniorrhaphy in a buffalo was reported by Kamalakar *et al.* (2015). Umbilical herniation of large colon in a five-month-old foal was reported by Bodaan *et al.* (2014), which suggested the chances of occurrence of even large intestinal herniation through the umbilical region in animals. So the conditions should be properly explored and corrective measures should be adopted.

#### SUMMARY

Umbilical hernia is one of the common types of hernia seen in calves due to multifactorial aetiologies. It has breed, age and sex predispositions according to previous studies. With appropriate surgical management, hernia and its complications can be corrected completely.

**Ethics statement:** This study does not involve animal experimentation and was conducted on cases reported in the hospitals, following standard operating protocols of animal handling and sample examination, upon informed consent of owners.

#### REFERENCES

- Baird, A.N. 2008. Umbilical surgery in calves. *Vet. Clin. North Am. Food Anim.* **24**(3): 467-477.

- Baird A.N. 2016. Surgery of the Umbilicus and Related Structures. *Vet. Clin. North Am. Food Anim.* **32**(3): 673-685. doi: 10.1016/j.cvfa.2016.05.008.
- Bendavid, R., Abrahamson, J., Arregui, M. E., Flament. J. B., Philips, E. H. (Eds.). 2001. *Abdominal wall hernias: principles and management*, Springer-Verlag, New York. U.S.A. pp. 36-63.
- Bodaan, C.J., Panizzi, L., Stewart, A.J., Cypher, E., Whitfield, L., Riley, C.B. 2014. Extensive umbilical herniation of the large colon in a foal. *Equine Vet. Edu.* **26**(7): 341-344.
- Demirkiran, A.E., Özgün, H., Balkaya, M., Çevikel, H., Çulhaci, N., Gürel, M. 2003. Strangulated ventral hernia model in rats. *J. Invest. Surg.* **16**(2): 93-97.
- Doijode V., 2019. Umbilical hernia in ruminant calves: A review. *J. Pharm. Innov.* **8**(4): 164-167
- Field J.R. 1988. Umbilical hernia with abomasal incarceration in a calf. *J Am Vet Med Assoc.* **192**(5): 665-666.
- Fubini, S.L., Smith, D.F. 1984. Umbilical hernia with abomasal-umbilical fistula in a calf. *J. Am. Vet.* **184**(12): 1510.
- Hondele, J. 1986. *Felduntersuchungen über Kälberverluste und Mißbildungen in Milchviehbetrieben. Thesis, Veterinary Medicine*, University of Munich.
- Heniford B.T., Park A., Ramshaw B.J., Voeller G. 2015. Laparoscopic repair of ventral hernias: nine years' experience with 850 consecutive hernias. *Ann. Surg.* **238**(3): 391-9
- Kamalakar, G., Prasad, V. D., Devaratnam, J., Ganeshan, A. 2015. Pyloro-duodenal hernia with formation of enterocutaneous fistula in a buffalo calf following a dog attack. *Open Vet. J.* **5**(2): 127-129.
- Müller, W., Schlegel, F., Haase, H., Haase, G. 1988. *Zumangeborenen Nabelbruch beim Kalb. Monatshefte für Veterinärmedizin* **43**: 161–163.
- Pardon, B., Vertenten, G., Durie, I., Declercq, J., Everaert, D., Simoens, P., Deprez, P. 2013. Four cases of omental herniation in cattle. *Vet. Rec. Case Rep.* **165**(24): 718-721
- Rijkenhuizen, A.B., Sickmann, H.G. 1995. Incarcerated umbilical hernia with enterocutaneous fistula in a calf. *Tijdschrift voor diergeneeskunde.* **120**(1): 8-10.



Ron, M., Tager-cohen, I., Feldmesser, E., Ezra, E., Kalay, D., Roe, B., Seroussi, E., Weller, J. I. 2004. Bovine umbilical hernia maps to the centromeric end of *Bos Taurus* autosome. *Int. Soc. Ani. Genet.* **35**: 431–437.

Singh, J., Fazili, M.R., Chawla, S.K., Tayal, R., Behl, S.M., Singh, S. 2006. Current status of diaphragmatic hernia in buffaloes with special reference to etiology and treatment: a review. *Indian J. Vet. Surg.* **27**(2): 73-79.

Sutradhar, B.C., Hossain, M.F., Das, B.C., Kim, G., Hossain, M.A. 2009. Comparison between open and closed methods of herniorrhaphy in calves affected with umbilical hernia. *J. Vet. Sci.* **10**(4): 343-347.

Virtala, A.M.K., Mechor, G.D., Grøhn, Y.T., Erb, H.N. 1996. The effect of calf hood diseases on growth of female dairy calves during the first 3 months of life in New York State. *J. Dairy Sci.* **79**(6): 1040-9.



---

## MOLECULAR DIAGNOSIS OF LUMPY SKIN DISEASE IN A CROSSBRED COW – FIRST CONFIRMED REPORT FROM KERALA

Sulficar S.<sup>1\*</sup>, Sudhakar Goud K.<sup>2</sup>, Krupa Rose Jose<sup>3</sup> and Vijayakumar K.<sup>4</sup>

<sup>1</sup>Assistant Professor, <sup>2</sup>Ph.D. Scholar, <sup>3</sup>M.V.Sc. Scholar, <sup>4</sup>Professor and Head Department of Veterinary Epidemiology and Preventive Medicine, College of Veterinary and Animal Sciences, Mannuthy, 680 651

\*Corresponding author: [drsulficars@gmail.com](mailto:drsulficars@gmail.com)

---

### ABSTRACT

This paper reports clinical management of lumpy skin disease in a cow that was presented with nodular eruptions on skin to University Teaching Veterinary Clinical Complex, Mannuthy. A thorough physical examination revealed that the cow had fever and small to large sized circumscribed nodules distributed though out the body. Swelling of both prescapular and prefemoral lymph nodes was noticed. Based on the history, clinical findings and PCR result the case was confirmed as lumpy skin disease (LSD). The case was managed vigorously with combination therapy and interestingly the cow recovered. This is the first confirmed report of LSD from Kerala.

**Keywords:** Lumpy Skin Disease, Cow, Treatment, Kerala

### INTRODUCTION

Lumpy Skin Disease (LSD) is a vector borne viral disease of cattle and

Asian water buffalo, characterized by fever and skin nodules. When introduced into naive population, the disease can cause substantial economic losses, both direct and indirect, the estimated direct production loss being 40 to 60 per cent. Etiological agent belongs to the genus Capripox virus in the Poxviridae family (Tuppurainen and Oura, 2012) and transmitted mechanically by arthropod vectors (Lubinga *et al.*, 2014). The disease epizootics were associated with high rain fall and high levels of insect activity, which peaked in late summer and autumn (Gari *et al.*, 2010). Lumpy skin disease could be classified into mild and severe forms based on number of lumps (nodules) and occurrence of complications that included, involvement of mucous membranes of respiratory, urogenital systems and other internal organs (Tageldin *et al.*, 2014). In severe cases, high fever (40-41.5°C) which persisted for one week, depression, anorexia, excessive salivation, enlargement of subscapular and pre-femoral

lymph nodes, decreased milk production, abortion, temporary or permanent sterility, damage to hides and mortality were noticed (Tuppurainen *et al.*, 2017). The recovery of animals from infection was very slow due to secondary bacterial infection and deep holes appeared in the skin due to fly strike (Al-Salihi, 2014). Tulman *et al.* (2001) reported LSD virus as a very stable virus, which survived well in the environment and inside the scabs shed by infected animals. Diagnosis of LSD is based on characteristic skin lesions and confirmation by laboratory tests. Whole blood, serum, oral and nasal swabs, skin nodules, scabs and lymph node biopsy are collected and sent to laboratory for confirmation of the disease. According to Abutarbush *et al.* (2015), only symptomatic treatment of LSD was possible, using combination of antimicrobial and anti-inflammatory drugs, to prevent secondary bacterial complications.

The disease was first reported in Zambia of African continent in 1929 and later on spread to whole African continent except Libya, Algeria, Morocco and Tunisia (Tuppurainen and Oura, 2012).

According to OIE, the first report of LSD from India was on 12/08/2019 from Khairbani, Mayurbhanj district of Orissa, then from Pataliputra on 17/08/2019 and from Rajendrapur of Bhadrak district on

20/08/2019 and the disease was confirmed on 16/11/2019. Based on phylogenetic analysis, the strain present in India was genetically close to South African NI2490/KSGP-like strains rather than European strains (Sudhakar *et al.*, 2020).

### **CASE HISTORY AND OBSERVATIONS**

On 22<sup>nd</sup> November, 2019 a crossbred cow aged four and half years from Vaniyampara, in Thrissur district of Kerala was presented to the TVCC, Mannuthy with the history of anorexia, reduction in milk yield and eruptions on skin (Fig.1). On clinical examination, temperature was 104.2°F, hyper salivation, lacrimation, nasal discharge, oedema of hind limb, difficulty in walking and prominent skin nodules over head, neck, perineum, genitalia and limbs were noticed. Scabs were seen fallen off from few nodules, unveiling wounds which were attracting flies. Severe lymphadenopathy of both prescapular and prefemoral lymph nodes was also observed. Since the clinical signs were suggestive of Lumpy Skin Disease, whole blood in EDTA vial, swabs from saliva and nasal discharge were collected and following the triple packaging system for the packing and labelling of infectious substances mentioned in OIE Terrestrial Manual 2013, the samples were forwarded from Department of Veterinary

Epidemiology and Preventive Medicine, College of Veterinary and Animal Sciences, Mannuthy to National Institute of High Security Animal Disease (NISHAD), Bhopal as per the advisory from Govt. of India for confirmatory diagnosis. Based on history and clinical signs the case was suspected for LSD and later it was confirmed as LSD by NISHAD by PCR and Real Time PCR on the saliva and nasal discharge (letter No 15-29/2019 NISHAD/2 dated 27/12/2019). This is the first confirmed report of LSD (a vector borne Capripox virus disease of cattle) from Kerala as per the available literature.

#### TREATMENT AND DISCUSSION

The cow was treated with Inj. Enrofloxacin @ 5 mg/kg (i/m), Inj. Flunixin meglumine @ 1.1mg/kg (i/v) for 5 days and advised herbal fly repellent spray to be applied locally on the skin to alleviate the clinical signs. The animal responded to the treatment and clinical improvement was noticed after one month. The temperature dropped to 102.4°F and 100.2°F after 24 and 48 hours of post-treatment, but nodules persisted during the course of treatment. After one month of treatment the cow recovered and nodules disappeared, but with scars on the skin.

The LSD is usually manifested as multiple, firm circumscribed nodules



Fig. 1. LSD with nodules all over the body

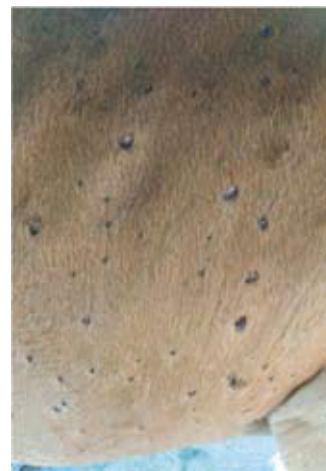

Fig. 2. Skin with scars after resolution of clinical signs

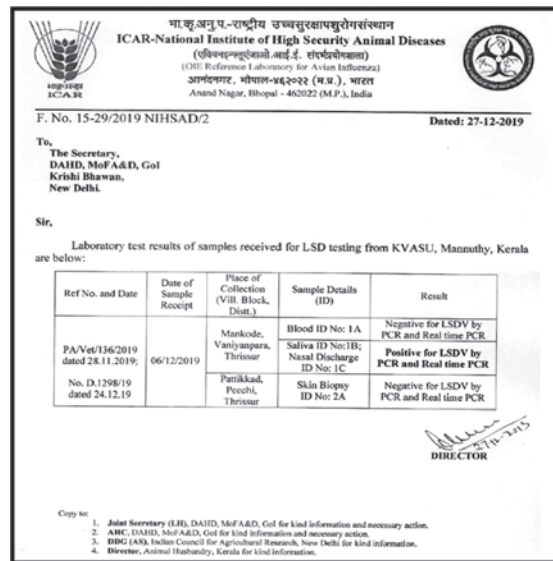
on the skin of head, neck, perineum, genitalia, udder, and limbs. The regional lymph nodes were enlarged 3-5 times their normal size and easily palpable. In most cases, the lesions may complicate or extend to other underlying tissues or internal organs (Abutarbush *et al.*, 2013). In LSD, the morbidity varied between 2 to 45 per cent and mortality rate was usually less than 10 per cent, but the economic losses accompanying LSD were higher. The losses were significant due to

decreased milk production, weight loss, abortion, infertility, and damaged hides (Babiuk et al., 2008). Therefore, systemic antibiotic and anti-inflammatory drugs were mandatory for treatment of skin infections, cellulitis or pneumonia to avoid further complications and economic losses (Al-Salihi et al., 2014). Maruthi et al. (2017) suggested Enrofloxacin as preferred antibiotic for treatment of skin infection, and in the current case, we used 10 per cent Enrofloxacin along with Flunixin meglumine. Animal showed remarkable improvement leaving scars on the healed skin (Fig. 2).

**SUMMARY**

The clinical presentation and treatment of the first confirmed case of LSD in Kerala in a cow is described. Treatment of secondary bacterial infection was successful with Inj. Enrofloxacin @ 5 mg/kg (i/m), Inj. Flunixin meglumine @ 1.1mg/kg (i/v) for 5 days and topical application of herbal fly repellent spray. Clinical improvement was noticed after one month leaving the scars on the healed skin.

**Ethics statement:** This study does not involve animal experimentation and was conducted on cases reported in the hospitals, following standard operating protocols of animal handling and sample examination, upon informed consent of owners.



Report from NIHSAD 27/12/2019

**REFERENCES**

Abutarbush, S.M., Ababneh, M.M., Al Zoubi, I.G., Al Sheyab, O.M., Al Zoubi, M.G., Alekish, M.O. and Al Gharabat, R.J. 2015. Lumpy Skin Disease in Jordan: Disease Emergence, Clinical Signs, Complications and Preliminary-associated Economic Losses. *Transbound. Emerg. Dis.* **62**: 549-554.

Al-Salihi, K. 2014. Lumpy skin disease - Review of literature. *Mirror Res. Vet. Sci.* **3**: 6-23.

Babiuk, S., Bowden, T.R., Parkyn, G., Dalman, B., Manning, L., Neufeld, J., Embury-Hyatt, C., Copps, J. and Boyle, D.B. 2008. Quantification of lumpy skin disease virus following



- experimental infection in cattle. *Transbound. Emerg. Dis.* **55**: 299-307.
- Gari, G., Waret-Szkuta, A., Grosbois, V., Jacquiet, P. and Roger, F. 2010. Risk factors associated with observed clinical lumpy skin disease in Ethiopia. *Epidemiol. Infect.* **138**: 1657-1666.
- Lubinga, J.C., Tuppurainen, E.S., Coetzer, J.A., Stoltz, W.H. and Venter, E.H. 2014. Evidence of lumpy skin disease virus over-wintering by transstadial persistence in *Amblyomma hebraeum* and transovarial persistence in *Rhipicephalus decoloratus* ticks. *Exp. App. Acarol.* **62**: 77-90.
- Maruthi, S.T., Prasad, C.K., Belakeri, P., Sagar, R.S. and Chethan, G.N. 2017. Diagnosis and Treatment of Bovine Dermatophilosis. *Intas Polivet*, **18**: 85-87.
- Sudhakar, S.B., Mishra, N., Kalaiyarasu, S., Jhade, S.K., Hemadri, D., Sood, R., Bal, G.C., Nayak, M.K., Pradhan, S.K. and Singh, V.P. 2020. Lumpy skin disease (LSD) outbreaks in cattle in Odisha state, India in August 2019: Epidemiological features and molecular studies. *Transbound. Emerg. Dis.* **1**: 1-15
- Tageldin, M.H., Wallace, D.B., Gerdes, G.H., Putterill, J.F., Greyling, R.R., Phosiwa, M.N., Al Busaidy, R.M. and Al Ismaaily, S.I. 2014. Lumpy skin disease of cattle: an emerging problem in the Sultanate of Oman. *Trop. Anim. Health Prod.* **46**: 241-246.
- Tulman, E.R., Afonso, C.L., Lu, Z., Zsak, L., Kutish, G.F. and Rock, D.L. 2001. Genome of lumpy skin disease virus. *J. Virol.* **75**: 7122-30.
- Tuppurainen, E.S.M. and Oura, C.A.L. 2012. lumpy skin disease: an emerging threat to Europe, the Middle East and Asia. *Transbound. Emerg. Dis.* **59**: 40-48.
- Tuppurainen, E., Alexandrov, T. and Beltrán-Alcrudo, D. 2017. Lumpy skin disease field manual—A manual for veterinarians. *FAO Anim. Prod. Health Man.* **20**: 1-60.

---

## EQUINE HERPES VIRUS ASSOCIATED NUMMULAR KERATITIS IN A MULE - A CASE REPORT

RamaRaju Sagi S.B.<sup>1\*</sup>, Kirun Poodari<sup>2</sup>, Choubey S.K.<sup>3</sup> and Amit Kumar<sup>4</sup>

<sup>1</sup>Lab Officer, Central Military Veterinary Laboratory (CMVL), Meerut Cantt - 250001.

<sup>2</sup>Veterinary Officer, 6 Advance Field Veterinary Hospital (AFVH), Bareilly Cantt.

<sup>3</sup>Commandant, CMVL, Meerut Cantt., <sup>4</sup>CMVL, Meerut Cantt

\*Corresponding author: sbrsagi.831h@gov.in

---

### ABSTRACT

Equine Herpes Virus- 1 (EHV-1) is a widespread viral pathogen in equines causing significant mortality and affections like respiratory disease, abortions and devastating Equine Herpes Myeloencephalitis (EHM). The article presents PCR confirmation of EHV-1 from equine keratitis. The affected eye of the animal had nummular keratitis with coin shaped (Nummular) lesions on the corneal stroma. Nummular keratitis a feature of viral kerato-conjunctivitis in humans. More experimental studies are needed to understand the pathogenesis of EHV-1 induced equine ocular infections. To the authors' knowledge, this is the first ever clinical case report of EHV-1 from equine corneal disease from India.

**Keywords:** Equine Herpes Virus-1, Keratitis, Fluorescein test

### INTRODUCTION

Corneal affections are commonly observed in horses. They are sight-

threatening diseases requiring early clinical diagnosis, laboratory confirmation and appropriate therapy. Corneal affections of the equine eye may present initially as minor corneal epithelial ulcers or equine ulcerative keratitis with full-thickness corneal perforations. Complications like globe rupture, phthisis bulbi and blindness occur in untreated cases (Brooks, 2002). Several viral, bacterial and fungal pathogens have been incriminated in corneal disease in equines. Equine Herpes virus and Adeno viruses are considered to be viral causes of corneal diseases in equines. Few authors have reported Equine Herpes Virus (EHV) in equine ocular infections, especially in experimental models of EHV-1 infections (Hussey *et al.*, 2013 and HolzN *et al.*, 2019). EHV-1 associated chorioretinitis was first described in the late 1980's in llamas and alpacas and then in a mare and foal during a natural outbreak of paralytic EHV-1 infection (Whitwell *et al.*, 1992). The article presents detection of EHV-1 from an equine keratitis case.

**CASE HISTORY AND OBSERVATIONS**

A five year old mule with clinical lesions of keratitis was presented at 6 Advance Field Veterinary Hospital, Bareilly Cantonment, Uttar Pradesh. The animal exhibited slight pain with epiphora and photophobia in the left eye. The affected left eye had nummular keratitis with coin shaped (Nummular) lesions on the corneal stroma. The eye was subjected to fluorescein dye test. The animal showed multiple, round, sharply delineated, greyish white areas, throughout the cornea with presence of marked inflammation and vascularization in the eye with slight dye retention (Fig. 1). Corneal scrapings were collected from the case and were sent to Central Military Veterinary Laboratory (CMVL) for diagnosis.

Corneal scrapings were subjected to bacterial and fungal isolation. The samples did not yield any bacterial growth after 48 hrs of incubation or any fungal growth on enriched media after 5 days of incubation. The samples were further tested

for presence of EHV-1 to rule out Herpes virus related viral keratitis and the corneal scrapings were positive for EHV-1 on PCR (Fig. 2). The details of primers and PCR conditions (Gupta *et al.*, 1996) are given in Table 1.

**TREATMENT AND DISCUSSION**

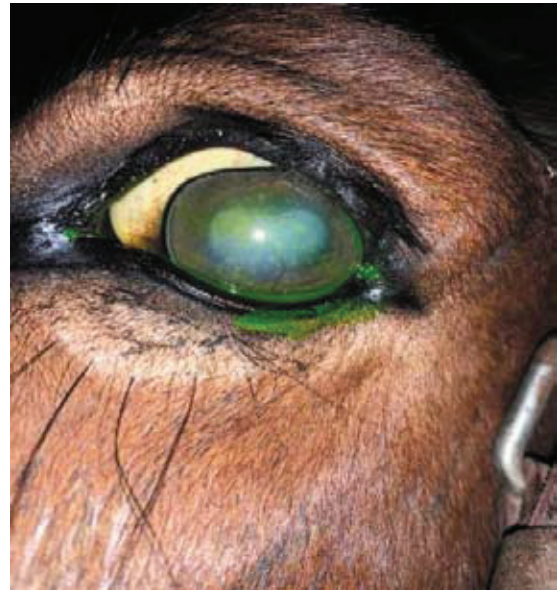As there is no approved treatment for EHV-1 in keratitis cases, the treatment may include anti-inflammatory drugs to alleviate pain and antibiotics to counter secondary bacterial infections. In the present case, supportive treatment with antibiotic (Neosporin ophthalmic solution) and NSAID (0.03 per cent Flurbiprofen eye drops) thrice daily was followed for two weeks and the animal showed improvement in clinical signs after three weeks of antibiotic treatment. Three weeks after the initiation of treatment, the corneal scraping of the animal was negative for EHV-1 on PCR. An anti-viral compound, Valacyclovir significantly decreased the viral replication and signs of disease in

**Table 1:** Details of PCR for EHV-1

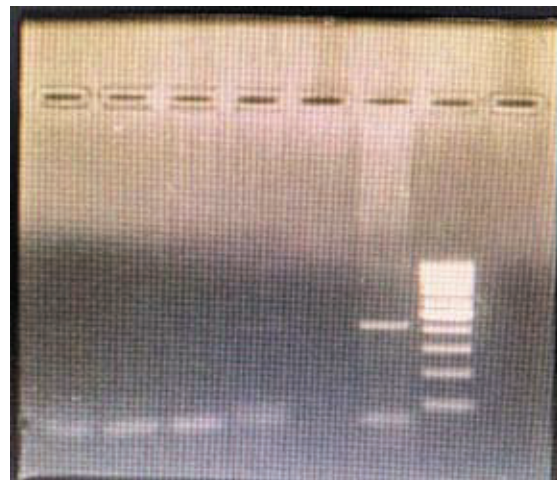Sl. No:	Primer sequence (5' to 3')	PCR Amplification	PCR product
01	Forward primer: CTGTAGCATA GAATGGTACAGAGGA; Reverse primer: CCCC GCAAGTA ACGGCGATGATGC	30 Cycles and each cycle included DNA denaturation at 95° for 01 min, annealing at 60 °C for 01 min and extension at 72°C for 03 min	409 bp

EHV-1–infected horses in a study by Maxwell *et al.* (2017).

Pathogenic keratitis in horses may present with a mild, early clinical course, but require prompt diagnosis and therapy. Microbiological culture and sensitivity for bacteria and fungi are recommended for horses with rapidly progressing and deep corneal ulcers. In the present case report, bacterial, fungal and viral aetiologies were investigated. Viral keratitis is seen as a superficial punctate keratitis but is uncommon. Literature on ocular EHV incidence is limited especially in clinical cases (Hollingsworth *et al.*, 2015 and Holz *et al.*, 2019). Despite vaccination, EHV-1 is a widespread viral pathogen in the worldwide equine population causing significant mortality and affections like respiratory disease, abortions and devastating Equine Herpes Myeloencephalitis (EHM). It is postulated that EHM and ocular EHV-1 have similar pathogenesis. Frequency of ocular EHV-1 was determined to be 50-90 per cent following experimental infection by intranasal instillation (Hussey *et al.*, 2013). The term “nummular keratitis” was first used by von Stellwag in 1889 for the lesions which have a tendency to break down and ulcerate (Woods, 1946). Nummular keratitis, as observed in the present case, is a feature of viral keratoconjunctivitis in humans and represent an immune-mediated corneal stromal reaction



**Fig. 1.** Nummular keratitis (multiple, round, sharply delineated, grayish white areas) and vascularization of the affected eye. The eye lesion was positive for EHV-1 on PCR.



**Fig. 2.** EHV-1 PCR product of 409 bp

to viral antigens. EHV-1 is also known to cause chorioretinopathy presenting as permanent focal or multifocal “shotgun” lesions of the chorioretina in a substantial proportion of infected horses (Hussey *et al.*, 2013). More experimental studies are needed to understand the pathogenesis of

EHV-1 induced equine ocular infections. Though incidences of EHV in mules was reported, literature on EHV in ophthalmic cases is scarce (Mekonnen *et al.*, 2017 and Ataseven *et al.*, 2009).

Stringent quarantine and bio-security measures must be implemented immediately if EHV is detected in the farm, as there is risk of infection to other animals in the farm. For horses that develops fever with positive EHV-1 test, or having a high risk of exposure, use of anti-viral drugs may decrease the chances of EHM. Drugs like Acyclovir and ganciclovir were also found to be active against EHV-1, EHV-4 and EHV-3 *in vitro* (Vissani *et al.*, 2016). More research is required on the efficacy of these drugs, their cost effectiveness, and the optimal dosing regimen for EHV associated disorders.

## SUMMARY

The systematic approach to obtain resolution of the ocular infections requires appropriate clinical examination and laboratory diagnosis to initiate proper therapeutic regimen and prevent subsequent complications. This paper reports incidental detection of EHV-1 induced viral keratitis in a working mule. The occurrence of viral keratitis due to EHV-1 in working equines in India warrants more studies to be accurately commented upon with respect to its incidence, treatment and prognosis.

To the authors' knowledge, this is the first ever Indian case report of demonstration of EHV-1 induced viral keratitis in equines.

## ACKNOWLEDGEMENT

The authors are thankful to the Directorate General Remount Veterinary Services (DGRVS), Quartermaster General's (QMG) Branch, Integrated Headquarters of Ministry of Defence (Army), for providing the necessary facilities to carry out the work.

**Ethics statement:** This study does not involve animal experimentation and was conducted on cases reported in the hospitals, following standard operating protocols of animal handling and sample examination, upon informed consent of owners.

## REFERENCES

- Ataseven, V.S., Dagalp, S.B., Guzel, M., Başaran, Z., Tan, M.T. and Geraghty, B. 2009. Prevalence of equine herpesvirus-1 and equine herpesvirus-4 infections in equidae species in Turkey as determined by ELISA and multiplex nested PCR. *Res. Vet. Sci.* **86**(2): 339-344.
- Brooks, D.E. 2002. Equine Ophthalmology. In: Proceedings of the Annual Convention of the AAEP. pp. 300-313



- Gupta, A.K., Singh, B.K., and Yadav, M.P. 1996. Application of polymerase chain reaction (PCR) for diagnosis of equine herpes virus-1 (EHV-1). *Indian J. Exp. Biol.* **34**(11): 1077-1080.
- Hollingsworth, S. R., Pusterla, N., Kass, P. H., Good, K. L., Brault, S. A., and Maggs, D.J. 2015. Detection of equine herpesvirus in horses with idiopathic keratoconjunctivitis and comparison of three sampling techniques. *Vet. Ophthalmol.* **18**(5): 416-421.
- Holz, C.L., Sledge, D.G., Kiupel, M., Nelli, R.K., Goehring, L.S. and Soboll Hussey, G. 2019. Histopathologic findings following experimental equine herpesvirus 1 infection of horses. *Front. Vet. Sci.* **6**: 59.
- Hussey, G.S., Goehring, L. S., Lunn, D.P., Hussey, S. B., Huang, T., Osterrieder, N., Powell, C., Hand, J., Holz, C. and Slater, J. 2013. Experimental infection with equine herpesvirus type 1 (EHV-1) induces chorioretinal lesions. *Vet. Res.* **44**(1): 118.
- Maxwell, L.K., Bentz, B.G., Gilliam, L.L., Ritchey, J.W., Pusterla, N., Eberle, R., Holbrook, T.C., McFarlane, D., Rezabek, G.B., Meinkoth, J. and Whitfield, C. 2017. Efficacy of the early administration of valacyclovir hydrochloride for the treatment of neuropathogenic equine herpesvirus type-1 infection in horses. *Am. J. Vet. Res.* **78** (10): 1126-1139.
- Mekonnen, A., Eshetu, A. and Gizaw, D. 2017. Equine herpesvirus 1 and/or 4 in working equids: seroprevalence and risk factors in North Shewa Zone, Ethiopia. *Ethiop. Vet. J.* **21**(2): 28-39.
- Vissani, M.A., Thiry, E., Dal Pozzo, F. and Barrandeguy, M. 2016. Antiviral agents against equid alphaherpes viruses: Current status and perspectives. *Vet. J.* **207**: 38-44.
- Whitwell, K.E. and Blunden, A.S. 1992: Pathological findings in horses dying during an outbreak of the paralytic form of Equid herpesvirus type 1 (EHV-1) infection. *Equine Vet. J.* **24**: 13-19.
- Woods, A.C. 1946. Nummular keratitis and ocular brucellosis. *Arch. Ophthalm.* **35**(5): 490-508.

