
OCCURRENCE OF FATAL GASTROINTESTINAL PARASITISM IN GOATS OF CENTRAL KERALA

Divya C.^{1*} and Mammen J. Abraham²

¹Assistant Professor, ²Associate Professor & Head (Retd), Department of Veterinary Pathology, College of Veterinary & Animal Sciences, Mannuthy-680651

*Corresponding author: divyac@kvasu.ac.in

ABSTRACT

Goats are one of the oldest domesticated species of animal being reared for milk, meat, fur and skin. Parasitism continues to be an important concern for goat farmers around the world. Death due to parasitism is an important constraint associated with the rearing of goats. Statistical data available over the past 2 years in the Department of Veterinary Pathology, CVAS, Mannuthy shows that the death rate in goats due to gastrointestinal parasitism is alarming. As per history collected, scientific deworming is not in regular practice among goat producers. This suggests that timely evaluation of faeces and subsequent deworming is mandatory for profitable rearing of caprine species.

Key words : Goat, Gastrointestinal parasitism, Coccidiosis, Anaemia

INTRODUCTION

Goats are one of the oldest domesticated species of animals being reared for milk, meat, fur and skin across the world. Goat farming has become a profitable business since it requires a very low investment because of its multi-functional utility. Goat milk is used for producing milk powder, butter, cream etc. Goat flesh is a great source of consumable meat which is very tasty, nutritious, healthy and free from religious taboos. Goat wool is being used for many purposes and skin of goat plays a vital role in leather industry. As goats are small sized animals, they can be easily managed too. Commercial goat farming business is contributing greatly to the economy and nutrition of a country.

Goats are considered as sturdy animals since they can thrive well in extreme climatic conditions. In spite of all

these, goat farming has its own constraints, of which the one which is of paramount importance is the impact of gastrointestinal parasitism. Parasitism continues to be an important concern for goat farmers and producers around the world. Parasites cause disease when they are present in large numbers or when the host animal is weakened by any other disease or by poor nutrition (Fthenakis and Papadopoulos, 2018). Parasites, particularly those of the gastrointestinal tract of sheep and goats can cause irreversible damage or even death to the animal, reduced performance and economic loss for the producer. Animals that are overburdened with parasites show hindered reproductive performance, experience reduced growth rates, and become less productive (Rinaldi *et al.*, 2007). Death due to parasitism is an important constraint associated with the rearing of “poor man’s cow”.

MATERIALS AND METHODS

The present study was based on a retrospective analysis of the statistical data available in the Department of Veterinary Pathology over the past 2 years with respect to the necropsy examination of 154 goats. During the time period from 1st January 2018 to 31st December 2019, a total of 154 goats were brought to the Department of Veterinary Pathology, College of Veterinary and Animal Sciences, Mannuthy for post-

mortem examination. Detailed necropsy was conducted in all the animals brought for the purpose and the lesions observed were recorded systematically. Microscopic examination of intestinal contents was performed in all the carcasses for detecting the presence of parasite ova. Histopathologic examination of the intestine was done in representative cases shown to be positive for parasitism.

RESULTS AND DISCUSSION

Out of the 154 goats brought for necropsy examination, gastrointestinal parasitism could be observed in 51 animals accounting for 33 per cent of the total cases. Of these, 38 goats died due to heavy load of intestinal parasites and in the remaining 13 animals, parasitism was only an incidental finding in animals that died due to other reasons. This meant that 25 per cent of the total goats examined herein, died due to internal parasitism, which is a very disturbing scenario.

The age wise incidence of the fatal cases is depicted in Fig. 1. Fatal gastrointestinal parasitism is found to be more prevalent in goats below 6 months of age. This could be attributed to the fact that goats are slow to develop immunity (Ayaz *et al.*, 2020).

The parasites encountered during necropsy examination included

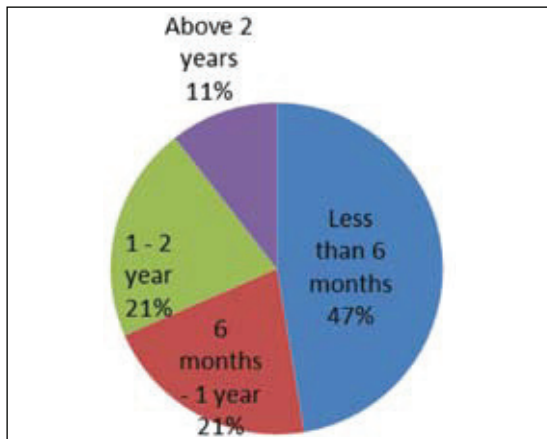


Fig. 1. Age-wise prevalence of fatal gastrointestinal parasitism

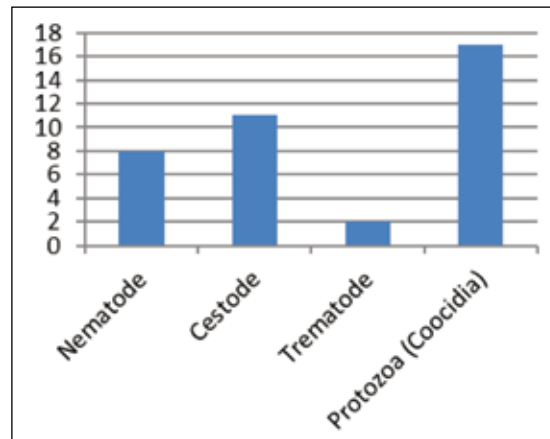


Fig. 2. Incidence of different category of parasites

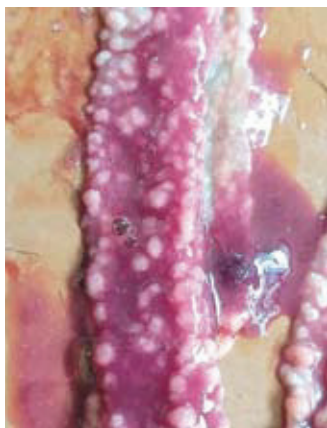


Fig. 3 Haemorrhagic enteritis with nodules in the intestinal mucosa

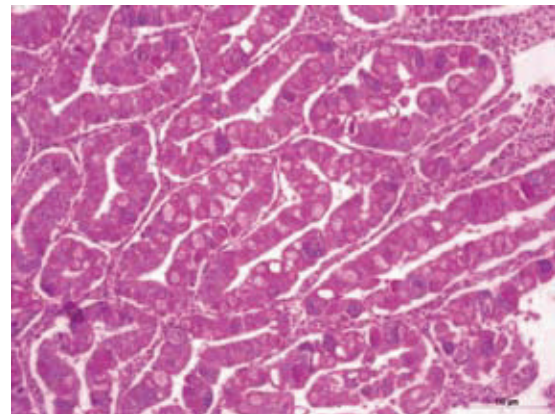


Fig. 4. Small intestine - intracytoplasmic developmental stages of *Eimeria* sp in the submucosal glands (H&E X 100)

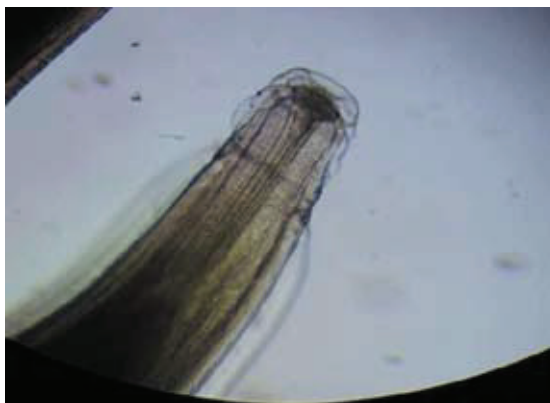

Fig. 5. *Oesophagostomum columbianum* - head end

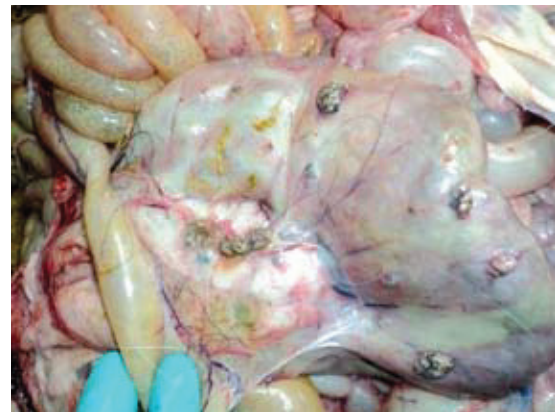

Fig. 6. Small intestine – Pimpley gut

nematodes like *Trichostrongylus* sp., *Oesophagostomum* sp., *Haemonchus* sp., *Trichuris* sp. and *Strongyloides* sp.;

cestodes like *Moneizia* sp. and *Taenia* sp.; trematodes like amphistomes and protozoa like *Eimeria* sp. The incidence

of coccidiosis was found to be more than helminths, as depicted in Fig. 2.

The intestinal lesions observed in carcasses of goats that died due to parasitism encompassed enteritis of varying degree. In coccidiosis, the most prominent lesion in intestine was severe haemorrhagic enteritis coupled with nodular eruptions in the mucosa (Fig. 3). The lesions observed were consistent with the findings of Chartier and Paraud (2012). Histopathologic examination of such nodules from small intestine unveiled the presence of intracytoplasmic developmental stages of *Eimeria* sp in the submucosal glands (Fig. 4). In cases of infection with the nematode, *Oesophagostomum columbianum* (Fig.5) pimply gut condition (Fig.6) could be observed. The extraintestinal lesions observed in animals died due to parasitism were mainly associated with hypoproteinemia and anaemia and comprised of cachexia, pale mucous membranes, pulmonary oedema, hydropericardium and ascites.

A review of the anamnesis revealed that sudden death without exhibition of any clinical signs is a common finding in animals that died due to parasitism. The study also revealed that scientific deworming of goats is not in regular practice among goat producers as per the

history collected in the department. This suggested that timely evaluation of faeces for the presence of ova/oocysts of parasites and subsequent strategic anthelmintic medication is an important requirement for profitable rearing of caprine.

A multitude of reasons could be enlisted to justify the reason for goats being the sufferers. Goats are browsers, they go for selective grazing thereby avoiding ingestion of infective larvae of worms present in the first 2 inches of vegetation. Valentine *et al.*, (2007), reported that exposure to worms was necessary to develop immunity; low levels of exposure were insufficient in conferring immunity to the host animals. Secondly, unlike sheep, goats were unable to reduce establishment of larvae within them or to expel adult parasites. Also, goats were slow to develop immunity and goat immunity was rarely effective against worms (Ayaz *et al.*, 2020). Another major reason that could be attributed to the finding was the widespread and growing anthelmintic resistance or drug tolerance by the worms.

SUMMARY

The present study was based on a retrospective statistical analysis of data available in the Department of Veterinary Pathology over the past 2 years with respect to the necropsy examination of 154

goats. Gastrointestinal parasitism could be observed in 51 animals, of which 38 goats died exclusively due to heavy load of intestinal parasites. The results suggest that gastrointestinal parasitism was found to be more prevalent in goats below 6 months of age. The incidence of coccidiosis was found to be higher than that of helminths. Sudden death without exhibition of any clinical signs was a common finding in animals that died due to parasitism. Timely evaluation of faeces for the presence of oocysts/ ova and subsequent strategic parasite management is mandatory for the profitable rearing of caprine species.

ACKNOWLEDGEMENT

The authors are thankful to the staff and students, CVAS, Mannuthy, KVASU for the constant support in the completion of this work.

REFERENCES

Ayaz, M.M., Sheikh, A.S., Aziz, M and Nazir, M.M. 2020. *Goat*

Immunity to Helminths. 10.5772/intechopen.91189.

Chartier, C. and Paraud, C. 2012. Coccidiosis due to *Eimeria* in sheep and goats, a review. *Small Rumin. Res.* **103**(1): 84-92.

Fthenakis, G.C. and Papadopoulos, E. 2018. Impact of parasitism in goat production. *Small Rumin. Res.* **163**: 21-23.

Rinaldi, L., Veneziano, V. and Cringoli, G. 2007. Dairy goat production and the importance of gastrointestinal strongyle parasitism. *Trans. R. Soc. Trop. Med. Hyg.* **102** (8): 745-746.

Valentine, B.A., Cebra, C.K. and Taylor, G.H. 2007. Fatal gastrointestinal parasitism in goats: 31 cases (2001–2006). *J. Am. Vet. Med. Assoc.* **231**(7): 1098-1103.

