
SURGICAL MANAGEMENT OF INTESTINAL OBSTRUCTION IN SIX CAMEL CALVES AND FOUR ADULT DROMEDARY CAMELS

Jamal, F. Rifat¹, Shejo Jose¹, Jayamohan, T.V.^{1*} and Rafeek, A.K.¹

*Madinat Zayed Veterinary Hospital, Department of Animal Health,
Abu Dhabi Agriculture and Food Safety Authority, Abu Dhabi, UAE*

**Corresponding author: gvjmohanan@yahoo.co.in*

ABSTRACT

Intestinal obstruction due to trichophytobezoars in six camel calves and four adult dromedary camels were surgically managed under xylazine and ketamine anesthesia. The obstructions were evident at the location of spiral colon. Length, width and wet weight of obstructed masses were studied. Enterotomy and laparotomy incisions were closed as per standard technique. Nine camels made an uneventful recovery. One adult camel died during surgery. Early surgical management is found to increase the survival rate in the case of intestinal obstruction in young and adult dromedary camels.

Keywords: Camel calf, intestinal obstruction, small intestine, spiral colon, phytobezoars

INTRODUCTION

Intestinal obstruction represents one of the common emergencies in camel

practice (Kahn *et al.*, 2010). Massive intestinal parasite infection, foreign bodies, and enlarged mesenteric lymph nodes are reported to cause intestinal obstruction (Ramadan *et al.*, 2008). Luminal blockages can occur in ruminants due to the formation of phytobezoars or trichobezoars in abomasum, which then pass into the small intestine (Blood *et al.*, 1985 and Khalphallah *et al.*, 2016). Clinical signs depended upon the position and degree of obstruction; including anorexia, straining, tympany and cessation of defecation (Eljalii *et al.*, 2014). In camels, liquefied ingesta propels quickly into the duodenum compared to other ruminants. The ingestion of fibrous plants and sand, licking of hair and habit of rolling in the sand predisposed them to intestinal obstruction (Tyagi and Singh, 1996). Surgical management of intestinal obstruction in six dromedary camel calves (1-2months old) and four adult camels due to tricho-phytobezoars is reported.

MATERIALS AND METHODS

Six dromedary camel calves and four adult camels with a history of constipation, anorexia, absence of defecation and dehydration for 1-2 weeks, were brought to Madinat Zayed veterinary hospital, Abu Dhabi, UAE. The calves were 1-2 months old. All the camels were medically managed by oral administration of laxatives like castor oil, liquid paraffin, olive oil, and magnesium sulfate powder. Intravenous fluid therapy using dextrose saline solution (5%) and normal saline was carried out for 3 days. Rectal enemas with liquid paraffin and lukewarm water were performed without any satisfactory result. All animals showed distended abdomen, signs of colic and constipation. Rectal temperature was ranging from 36-37°C. The mucous membranes were pale and there was grunting sound during deep abdominal palpation. Tentative diagnosis of intestinal obstruction was made in all cases.

Surgical procedure

The camels were sedated with a combination of 2% xylazine hydrochloride (0.2 mg/kg) and ketamine 10% (1mg/kg) intramuscularly and restrained in the left lateral recumbency. The right flank region was prepared for aseptic surgery. Local linear infiltration of 2% lignocaine hydrochloride was given. Laparotomy was

performed as per the standard procedure.

RESULTS AND DISCUSSION

Careful exploration of the abdominal cavity revealed multiple loops of small intestines distended with gas. Examination of the intestine revealed palpable hard mass lodged in the spiral colon in all cases (Fig. 1 and 2). The obstructed intestinal loops were carefully isolated and examined. Varying sizes of trichobezoars were removed through enterotomy, as shown in Table 1 and Fig. 3 and 4. The enterotomy and laparotomy incisions were closed by standard technique. Post-operative fluid therapy with dextrose normal saline was given intravenously for five days. Marbofloxacin (10%) at a dose of 2 mg/kg body weight and ketoprofen hydrochloride 2.2 mg/kg were administered intramuscularly for five days. The animals started passing loose foul-smelling stool within 24 hrs. post-surgery. Soft food was advised from the third day of operation. Post-operative wound was dressed daily. Skin sutures were removed on the twelfth postoperative day. One adult camel died during surgery due to delayed reporting and associated complications and shock. All the other camels made uneventful recovery (Fig. 5).

Abdominal disorders in dromedary camels can pose diagnostic and treatment challenges. Mild colic with abdominal

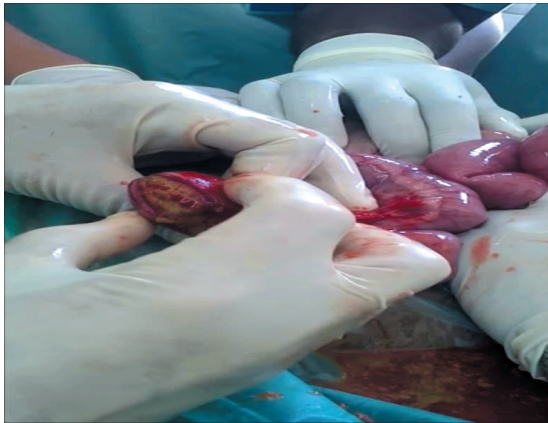


Fig. 1. Intraruminal mass obstructing the intestine

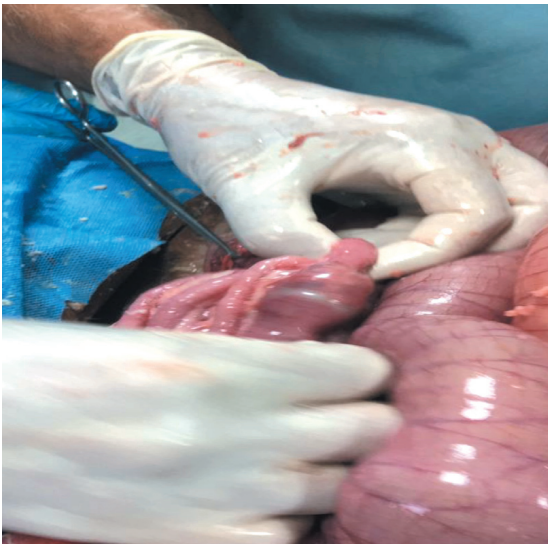

Fig. 2. Palpable hard mass lodged in the spiral colon.

distention and absence of fecal output in camelids indicated either mechanical or functional intestinal obstruction (Sullivan *et al.*, 2005). In camels, ingestion of fibrous shrubs and licking of hairs due to nutritional deficiency led to the formation of trichobezoars and phytobezoars respectively in the intestinal tract (Eljalii *et al.*, 2014). Intestinal obstruction may

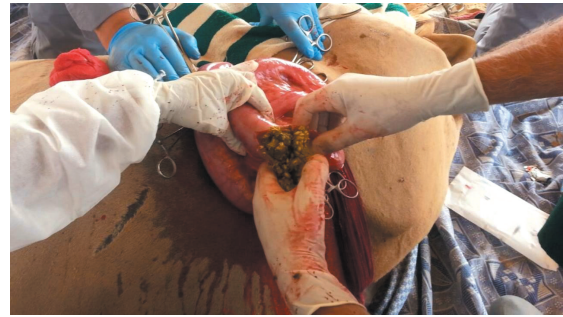

Fig. 3. Dry food was removed from the impacted loops.



Fig. 4. Hard mass removed from the impacted loops.



Fig. 5. The camel after one month of surgery.

occur when one of the zootrichobezoar or phytotrichobezoar finds its way into the intestine leading to an obstruction. In camelids, ingested foreign material was reported to form bezoars within the first gastric compartment and caused obstruction of critical size at the narrowest portion of

Table 1. Length, width and wet weight of the obstructed masses in the intestines of the camel calves.

Animal No.	Length (cm)	Width (cm)	Wet Weight (gm)
1	3.5	2.0	16.00
2	2.5	1.5	12.00
3	5.4	3.0	27.00
4	5.0	2.5	15.16
5	3.2	2.3	7.5
6	2.2	1.8	7.2

the gastric outflow tract (Sullivan *et al.*, 2005).

Obstruction involving the ileum and colon was reported in camels (Tayel *et al.*, 1985). Ingestion of sand and habit of camels rolling in the sand, predisposed them to torsion and mechanical obstruction of the intestine (Tyagi and Singh, 1996). When some of the undigested food materials accumulated as intraluminal mass, it caused obstruction in duodenum and jejunum termed as proximal or high obstruction, or in ileum and colon as distal or low obstruction (Tyagi and Singh, 1996). Camels suffering from 'pica' usually eat hair which lead to the formation of phytobezoars and trichobezoars that may reach the intestine causing an obstruction (Tanwar, 1985). Feed which is not easily digested can predispose to formation of faecoliths or impaction of the intestine particularly at the site of the spiral colon. Because a good amount of water is absorbed in the colon of the camel and

the fluidity of luminal content change into hard fecal balls than in the bovine, chronic intestinal obstructions warrant surgical intervention (Tyagi and Singh, 1996). The transrectal examination of the abdominal cavity of adult cattle with signs of intestinal obstruction is often a useful diagnostic aid; this is not possible in young calves because of the body size (Abutarbush and Radostits, 2004). The diagnosis of intestinal obstruction in young camel calves with a history of anorexia, complete absence of defecation for more than 3 days and failure to respond to parenteral fluid therapy, and oral administration of laxatives or rectal enema using warm water, that requires surgical intervention immediately (laparotomy). Surgery was considered to be the favorite method of treatment of such cases and should be considered when this condition was suspected (Abutarbush and Naylor, 2006).

The spiral colon in camelids had five coils (Fowler *et al.*, 2010). The proximal

loop was dramatically longer in proportion to the spiral colon when compared with that of true ruminants (Cebra *et al.*, 1998). Because exploratory laparotomy tends to be well tolerated by camelids, early surgical intervention should be performed on a timely manner when the cause of abdominal pain is in doubt (Costarella and Anderson, 1999) and (Bickers *et al.*, 2000). Therefore, the veterinarians must decide whether exploratory laparotomy is indicated on the basis of the result of clinical examination, hematological and biochemical analysis and ultrasonography as well as the value of the animal (Tharwat *et al.*, 2012).

Surgical management of intestinal obstruction should be considered in young camel calves, less than 1 year of age suffering from constipation, by right flank paracostal laparotomy which has a good prognosis (Sullivan *et al.*, 2005). Timely surgical management of intestinal obstruction by phytobezoars and trichobezoars gave rewarding results as the delay in presentation posed greatest challenge for the surgeon and the patient. Therefore, due to delay in reporting, the patients reach a critical point of poor surgical conditions, which affected outcome of the surgery. The duration of the small intestinal obstruction was negatively correlated to survival. Therefore, early diagnosis and surgical correction of intestinal obstruction

were thought to increase survival by decreasing the likelihood of regurgitation and aspiration pneumonia (Sullivan *et al.*, 2005). The following recommendations are given in the management of intestinal obstruction in camels.

RECOMMENDATIONS

1. Preventive management of ground containing sand by nylon sheets, which are used in greenhouses, prevents sand licking. The young calves should be fed on green feed when they start grazing.
2. Routine administration of laxatives in weekly interval is recommended to prevent any accumulation of semisolid ingesta in any point of the intestinal tract, especially in the spiral colon.
3. *Ad libitum* water supply should be available for all animals to prevent dehydration especially in the dry climate of the desert in the Arabian Gulf region.

SUMMARY

The occurrence of the intestinal obstruction is most common in camel calves of 1-3 months age group. Prompt surgical intervention is the only treatment of choice for the intestinal obstruction to save the life of the patient. Delayed response and ineffective treatment may result in serious complications, which may ultimately lead

to the death of the animal. The present study revealed successful surgical management of intestinal obstruction in camel calves as well as adult ones.

ACKNOWLEDGMENTS

The authors are grateful to Abu Dhabi Agriculture and Food Safety Authority and Mr. Sari Ghashim Almansoori, Director of the Veterinary Services section in the Aldhafra region for his encouragement and extending facilities.

REFERENCES

- Abutarbush, S.M. and Naylor, J.M. 2006. Obstruction of the small intestine by trichobezoars in cattle, 15 cases (1992-2002), *J. Am. Vet. Med. Assoc.* **229**: 1627-1630.
- Abutarbush, S.M. and Radostits, O.M. 2004. Obstruction of the small intestine caused by a hairball in 2 young beef calves. *Can. Vet. J.* **45**(4): 324-326.
- Bickers, R.J., Templer, A., and Cebra, C.K. 2000. Diagnosis and treatment of torsion of the spiral colon in an alpaca. *J. Am. Vet. Med. Assoc.* **216**: 380-382.
- Blood, D.C., Radostits O.M., and Henderson J.A, 1985. *Veterinary Medicine*, 6th Ed. ELBS. pp. 170-173.
- Cebra, C.K. 1998. Acute gastrointestinal diseases in 27 New World camelids; Clinical and Surgical findings. *Vet. Surg.* **27**(2): 112-121.
- Costarella, C.E. and Anderson, D.E. 1999. Ileogastric intussusception in a one-month-old llama, *J. Am. Vet. Med. Assoc.* **214**: 1640.
- Eljalii, I.M., Ramadan, O.R. and Al Mubarak, A.I. 2014. Trichobezoars associated with intestinal obstruction in a she-camel (*Camelus dromedaries*). *J. Camel Pract. Res.* **21**(2): 285.
- Fowler, M.E. 2010. *Practices in Med. & Surgery of camelids*. 3rd Ed. Blackwell Publishing, Iowa. Pp. 231-269.
- Kahn, C.M., and Line, S. 2010. Overview of acute intestinal obstruction in large animals. In: eBook Merck Vet. Med. Manual, 10th Ed. Merck & Co., Whitehouse Station, NJ.
- Khalphallah Arafat, Nasr-Eldin, M. Aref, Elmeligy, E. and Elhawari, S.F. 2016. Clinical and Ultrasonographic observations of functional and mechanical intestinal obstruction in Buffaloes (*Bubalus bubalis*). *Vet. World.* **9**(5): 475-480.
- Ramadan, R.O., Abdin-Bey, M.R., Mohammed, G.E.A, Bakhsh, A.A., Al-Mubarak, A.I. and Al-Butayan,

- A.K. 2008. Intestinal obstruction in camel. *J. Camel Pract. Res.* **15**: 71-75.
- Sullivan, E. K., Robert, J. Callan, Timothy, M. Holt and David, C.V. 2005. Trichobezoar duodenal obstruction in new world camelids. *Vet. Sur.* **34**(5): 524-529.
- Tanwar, R.K.,1985. Intestinal obstruction by phytobezoars in a camel- a case report. *Indian J. Vet. Med.* **5**: 31-32.
- Tayel, R., Sharma S.K., Singh M., Singh A.P. and Singh J. 1985. Obstruction of Colon due to faecoliths in a camel. *Haryana Vet. J.* **24**: 64-65.
- Tharwat, M., Fahad Al-sobayil, Ahmed Ali and Sebastien Buczinski. 2012. Ultrasono- graphic evaluation of abdominal distention in 52 camels. *Res. Vet. Sci.* **93**(1): 448-56.
- Tyagi, R.P.S., and Singh 1996. Ruminant surgery. CBS Publishers, New Delhi. pp. 217-218.
-