
ULTRASONOGRAPHIC AND RADIOGRAPHIC FEATURES OF RETICULO-PHRENIC ADHESIONS IN BUFFALOES

Rahul K. Udehiya^{1*}, J. Mohindroo² and S. S. Singh³

¹Assistant Professor, Department of Veterinary Surgery & Radiology,
Faculty of Veterinary and Animal Sciences, R.G.S.C.,
Banaras Hindu University, Barkachha, Mirzapur- 231001 (U.P.).

²Professor, Department of Veterinary Surgery & Radiology,
College of Veterinary Science, GADVASU, Ludhiana,

³Former Dean PGS, GADVASU, Ludhiana

*Corresponding author Email: vet.rahul@gmail.com, vet_rahul@bhu.ac.in

ABSTRACT

This study investigates reticulo-phrenic adhesion in four buffaloes through clinical assessments, laparotomy, radiography, and ultrasonography. Clinical manifestations included anorexia, mucus-coated dung, dehydration, and left flank distension. Vital signs were normal, and hematological tests revealed elevated neutrophil and reduced lymphocyte counts. Radiographs displayed soft tissue bands between the reticulum and diaphragm, while ultrasonography revealed an abnormal crescent-shaped reticulum lacking smooth contour and motility. Local anesthesia-assisted exploratory laparotomy confirmed moderate reticulo-phrenic adhesions. The study concludes that ultrasonography and radiography are effective diagnostic tools for diagnosis of reticulo-phrenic adhesions in bovines.

Keywords: Ultrasonography, Radiography, Reticulo-Phrenic Adhesions, Buffaloes

Introduction

Bovine forestomach afflictions resulting from foreign body ingestion are a global concern, particularly in the reticulum, contributing to issues like traumatic reticulo peritonitis, reticular abscess, reticulo-phrenic adhesions, and reticular diaphragmatic hernia. Manifestations encompass diminished milk production, anorexia, fever, and weight loss (Makhdoomi *et al.*, 2019). Common diagnostic tools include history assessment, clinical signs observation, hematology, blood biochemistry, ferrospectroscopy, radiography, and ultrasonography (Ramprabhu *et al.*, 2003). Despite these, distinguishing between traumatic reticulo peritonitis, diaphragmatic hernia, reticular abscess, and reticulo-phrenic adhesions can be challenging. Definitive diagnosis often necessitates exploratory laparotomy, while ultrasonography emerges as a pivotal diagnostic method for

bovine abdominal disorders, encompassing traumatic reticulo peritonitis, reticular adhesion, and reticular abscess (Braun, 2003).

MATERIALS AND METHODS

This study conducted on four buffaloes diagnosed with reticulo-phrenic adhesions, aged between 6-12 years, exhibiting prolonged anorexia and suspended rumination. Referred to the Department of Veterinary Surgery & Radiology, College of Veterinary Science, GADVASU, Ludhiana, suspected for forestomach disorders. A detailed clinical history, including feed and water intake, regurgitation, rumination, tympany, pregnancy status, and duration of illness, was recorded for each case. Comprehensive physical examinations evaluated general condition, rectal temperature, heart rate, respiration rate, hydration status, and rumen motility at presentation. Hematological and biochemical studies, following Jain's (1986) methods, were conducted, measuring parameters like Haemoglobin, Packed cell volume, Total leukocyte count, Differential leukocyte count, total plasma protein, Plasma fibrinogen, and Rumen chloride. Lateral radiographs of the thorax and abdomen were taken in three animals after casting them in right lateral recumbency to diagnose foreign bodies. Ultrasonography, utilizing a 3.5 MHz

micro convex transducer, was performed on all animals to assess reticular motility at the 6th-7th intercostal space. Exploratory laparo-rumenotomy was conducted in all cases, involving restraint in a standing position, aseptic preparation of the left flank, and local anesthesia. Laparotomy included incisions through skin, subcutaneous fascia, muscles, and peritoneum in the left paralumbar fossa. Peritoneal fluid quantity and adhesions were assessed before rumenotomy, during which up to 3/4th of rumen contents was evacuated, and foreign bodies, if present, were removed.

RESULTS AND DISCUSSIONS

All afflicted animals exhibited complete anorexia, indicative of potential disruptions in reticular motility due to perireticular adhesions. The water intake varied, with one animal displaying normal intake and two showing partial intake. The mean illness duration was 12.67 ± 2.33 days, recurrent tympany in two animals, and scanty constipated feces in three, indicating gastrointestinal complications. Notably, two animals were in late pregnancy or recently parturied. The mean rumen motility was recorded 3.00 ± 3.00 (per three minutes) which may be considered as normal. In contrast Rehage *et al.* (1995) and Ramprabhu *et al.* (2003) reported significantly reduced motility in cows suffering from localized reticular

adhesion. Clinical parameters, including heart rate, respiration rate, and rectal temperature, generally fell within normal ranges, aligning with earlier studies by Singh (2004) and Kumar (2006). However, all animals displayed poor body condition, with three exhibiting severe dehydration. Hematological analyses (Table 1) revealed elevated packed cell volume, potentially linked to dehydration, while total plasma protein levels were increased, indicating haemoconcentration due to dehydration. Slightly elevated plasma fibrinogen suggested an inflammatory process, consistent with reports in Indian buffaloes. Similar findings were recorded in buffaloes by Singh *et al.* (1972). Rumen chloride levels were slightly higher than normal, hinting at abomasal reflux.

Radiographs of three animals revealed soft tissue bands between the reticulum and diaphragm (Fig. 1), a strong indicator of reticulo-phrenic adhesions.

Reticulophrenic adhesions were diagnosed by radiography where the reticulum

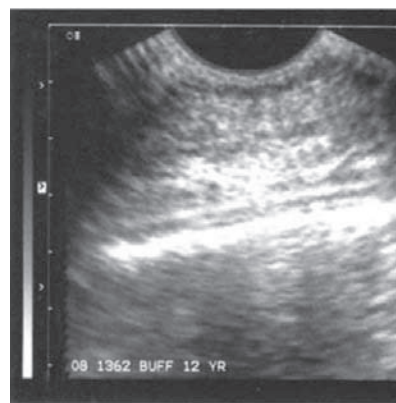


Fig. 1: Soft tissue density between reticulum and diaphragm with multiple penetrating and non-penetrating foreign bodies suggestive of reticulo-phrenic adhesion

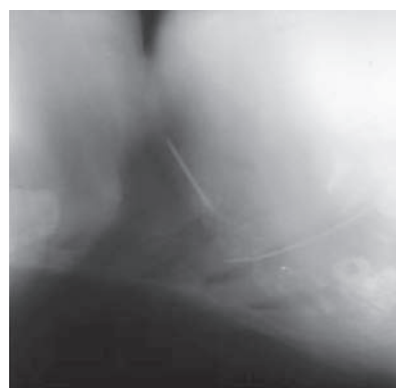

Fig. 2: Reticular wall evident as crescent shaped does not contract away from transducer in cases of reticulo-phrenic adhesions

Table 1: Mean ± SE value of haematological parameters

Parameter (Unit)	Value (Mean ±S.E.)
Haemoglobin (g/dL)	11.20±0.46
Packed Cell Volume (%)	37.33±2.33
Total leukocyte count (per cmm)	9066.67±2602.78
Neutrophil (%)	66.67±2.91
Lymphocyte (%)	36.67±4.67
Total plasma protein	9.40±2.11
Plasma fibrinogen (g/dL)	0.77±0.35
Rumen chloride (mEq/L)	48.00±12.47

and diaphragm were clearly visualized. Radiography was found to be reliable in the diagnosis of the conditions like atypically positioned foreign bodies, abnormal gas shadows in the region of the reticulum, and depression in the cranioventral margin of the reticulum (Braun *et al.*, 1993a). Ultrasonography was performed in all the animals suffering from reticulophrenic adhesions. The reticulum was scanned at 6th – 8th intercostal space starting from the level of right elbow slowly scanning down to the ventral midline. Ultrasonography confirmed these findings, with crescent-shaped reticular walls without motility in the affected area as described by earlier workers (Braun *et al.*, 1993b, Braun 2003).

Exploratory laparo-rumenotomy in all cases substantiated the ultrasound findings, confirming moderate reticulophrenic adhesions. Penetrating metallic foreign bodies were observed in two animals, emphasizing the role of diagnostic interventions, similar finding was recorded by Kumar (2006). The study underscores the diagnostic value of radiography and ultrasonography in detecting reticulophrenic adhesions and emphasizes the importance of exploratory laparo-rumenotomy for definitive confirmation. Findings align with previous literature, supporting the diagnostic utility of clinical,

radiographic, and ultrasonographic parameters in identifying reticulo-phrenic adhesions. Overall, the study contributes to the understanding of this condition in bovines, providing valuable insights into its clinical presentation and diagnostic nuances.

CONCLUSION

In conclusion, ultrasonography and radiography proved reliable for diagnosing reticulo-phrenic adhesions in bovines. Their synergy with clinical, hematological, and surgical methods enhances the accuracy of diagnosing this condition.

REFERENCES

- Braun, U. 2003. Ultrasonography in gastrointestinal disease in cattle. *Vet J.* 166 : 112-24.
- Braun, U., Fluckiger, M. and Nageri, F. 1993a. Radiography as an aid in the diagnosis of traumatic reticuloperitonitis in cattle. *Vet Rec* 132: 103-09.
- Braun, U., Gotz, M. and Marmier, O. 1993b. Ultrasonographic findings in cows with traumatic reticuloperitonitis. *Vet Rec* 133: 416-22.
- Jain, N. C. 1986. *Schalms Veterinary Haematology*, Lea and Febiger, Philadelphia, USA.

- Kumar, M. 2006. Studies on the diagnosis of reticular disorders in bovines. Ph.D thesis, Guru Angad Dev Veterinary and Animal Sciences University, Ludhiana, India. 26-37p
- Makhdoomi, SM, Sangwan, V, Kumar A and Mohindroo J. 2019. Ultrasonographic morphometry of reticulum in cattle and buffaloes suffering from traumatic reticulo-peritonitis. *Buffalo Bulletin* 38(3):421 – 436.
- Ramprabhu, R., Dhanapalan, P. and Prathaban, S. 2003. Comparative efficacy of diagnostic tests in the diagnosis of traumatic reticuloperitonitis and allied syndromes in cattle. *J. Israel Vet. Med. Assoc.* 58 (2-3):68–72.
- Rehage, J., Kaske, M., Stockhole, Z. N. and Yalcin, E. 1995. Evaluation of pathogenesis of vagus indigestion in cows with traumatic reticuloperitonitis. *J. Am. Vet. Med. Assoc.* 207: 1607-11.
- Singh, A. P., Joshi, H. C. and Singh, R. 1972. Studies on certain blood constituent in cattle and buffaloes. *Indian Vet. J.* 49: 473.
- Singh, G. 2004. Clinical studies on surgically treated reticulo-diaphragmatic and omasal disorder in bovines. M.V.Sc. thesis, Punjab Agricultural University, Ludhiana, India.