
COMMON VIRAL DISEASES AFFECTING PET BIRDS

Priya P. M¹, C. Udhayakumar² and V. Niranjana³

¹Professor and Head, ²Ph. D Scholar, ³MVSc Scholar

Department of Veterinary Microbiology,
College of Veterinary and Animal Sciences, Mannuthy, Thrissur- 680 651,
Kerala Veterinary and Animal Sciences University, Kerala, India.

ABSTRACT

Pet birds are usually raised as companions due to their vibrant personalities and interactive nature. Many bacterial and viral diseases can cause mortality in them, and these infections can be precipitated by stress and immunosuppression. Among pet birds, mortality due to viral diseases are frequently found in young psittacine and passerine birds. Throughout the last decade, a plethora of novel findings has illuminated the prevalence and significance of viral infections, notably including herpes, circovirus, and adenovirus. The most pathogenic Togaviridae family of viruses leading to increased mortality in young ones are also reported in these birds. Hence, understating the infectious mechanism of the common viral diseases of pet birds have become mandatory to arrive at a diagnosis. To move on for a definitive diagnosis and to rule out differentials, molecular methods as well as gross and histopathological findings can be helpful. Hence, a thorough knowledge regarding

characteristic clinical findings observed in various viral infections of pet birds will not only help in clarifying the pathobiology but will also assist in implementing the necessary control strategies. This review provides an in-depth examination of the typical viral infections found in pet birds, including an analysis of their causative agents, various viral strains, and the primary sites of infection.

Keywords: Psittacine, Passerine, Viral infections, Diagnosis

INTRODUCTION

Birds are increasingly forming social bonds with humans and are predominantly kept as companions. Additionally, they can be of benefit to the communities by serving as a source of revenue through trading across the countries. The term 'pet birds' mainly includes parrots, pigeons, canaries and finches. Majority of the viruses that are known to infect pet birds have been extensively studied. But some avian viruses are still unclassified and certain others have

not yet received enough research attention (Greenacre, 2005).

Psittacine and non-psittacine birds are often housed in flock aviaries for breeding purposes. The aviary can be a breeding aviary with a focus on a single species or it could be a mixed aviary housing several other species. Multiple species of birds in contact with each other can serve as a means by which infectious diseases can be transmitted. Each individual species of bird kept in captivity requires different dietary and husbandry needs and a failure to accomplish this can eventually lead to disease outbreaks. Diseases can also occur because of various stress factors like changes in nutrition, husbandry, breeding and also due to introduction of new birds into an existing population.

The diagnosis part plays an important and initial step in controlling the infection. Therefore, knowledge regarding the clinical symptoms and necropsy lesions caused by virions belonging to various viral families can be helpful in comprehending the course of the infection and to arrive at proper differential diagnosis. Most of the viral infection in pet birds exhibit multisystemic nature, so the confirmatory diagnosis of a particular viral infection is difficult, and it requires more knowledge regarding host specificity, predilection site of the virus and its disease

manifestation mechanism. Therefore, this review prioritizes the distinctive clinical presentations, host specificity, and disease manifestations exhibited by different subfamily of viruses, emphasizing their significance in understanding avian health. The following viral families are discussed; *Adenoviridae*, *Circoviridae*, *Herpesviridae*, *Papillomaviridae*, *Polyomaviridae*, *Poxviridae*, *Paramyxoviridae*, *Togaviridae* and a virus from an unclassified family along with other aetiologies causing proventricular dilatation disease.

Adenoviridae

There is a well-known pigeon adenovirus within the *Adenoviridae* family. Apart from that the International Committee on Taxonomy of Viruses states that there is an adenovirus particularly affecting *Psittacine* birds, which is not yet classified into the genus. Certain serotypes of adenovirus that affect chicken can also cause infections in pigeons. *Pigeon adenovirus* can affect pigeons from the day of hatch to the age of five; clinical symptoms are most frequently observed in birds between two to four months of age. Infections in young birds exhibiting the clinical symptoms can be lethal. The mortality rate peaks at three to four days after infection and ranges from 0 to 60% (Goodwin, 1992). Early in the infection process, the virus enters the host cell and

makes its way down to the nucleus, where it triggers the transcription and translation processes using early genes. The early phase is followed by the late phase, which redirects the cellular processes. Then there will be transcription and translation of late genes, and this allows the virus to code for structural proteins. Following this, the synthesised viral proteins assemble around the genome to form full virions within the infected cell nucleus. This is trailed by nuclear membrane disintegration leading to release of virions from the infected cells (Hess, 2013).

Clinical signs exhibited by psittacine birds infected with adenovirus includes depression, anorexia, and cloacal haemorrhage followed by hepatitis, enteritis, pancreatitis, encephalitis, splenitis and conjunctivitis ultimately leading to death. Birds that lacked clinical signs exhibited intranuclear inclusion bodies that were consistent with adenovirus infections of psittacine birds (Greenacre, 2005). Adenoviruses replicate in the nucleus and form basophilic intranuclear inclusion bodies that most often are recognized in hepatocytes as well as enterocytes (Soike *et al.*, 1998). Recently, Rinder *et al.* (2020) identified a partially sequenced novel adenovirus in passerine birds. *Siadenovirus* were host specific to the amphibians but, *F* - *Siadenovirus* of frogs infecting psittacine

birds has been reported by Vaz *et al.* (2020). Passerine adenovirus and Murine adenovirus - 2 are reported in pine Martens (Walker *et al.*, 2017) and in the droppings of Galahs (Vaz *et al.*, 2020) respectively, which indicates the host switching abilities of novel adenoviruses.

Circoviridae

A novel family of pathogenic *Circovirus* affecting feather follicles of the pet bird, cockatoo, was first identified in 1989. These viruses are among the smallest ones to be reported to date, measuring between 14 and 16 nm. They result in a condition known as psittacine beak and feather disease (Pbfd). Subsequent research revealed that circoviruses of geese and pigeons were antigenically different from the virus causing Pbfd (Woods *et al.*, 1994). Cockatoos, lovebirds, African grey parrots, and cockatiels are among the Old World psittacines that are most frequently affected by the Pbfd virus in both captivity and in the wild. Less frequently, the virus can cause clinical symptoms in psittacine birds native to the New World, including conures, macaws and Amazon species. A few cases of clinical Pbfd have been reported in New World species such as Jenday conures, red-lored and blue fronted Amazon parrots, and scarlet macaws (Greenacre *et al.*, 1992).

Parrots can develop the acute, chronic, and subacute forms of Pbfd. The clinical progression of the disease is determined by the age of the affected birds. According to Schoemaker *et al.* (2000) the illness advances more quickly in younger birds. Neonatal cockatoo and African grey parrots frequently experience per acute Pbfd, characterised by sepsis, pneumonia, enteritis, weight loss and death. In certain cases, liver necrosis, severe leukopenia, feather follicle oedema and bursal necrosis are seen. Acute Pbfd affects chicks that are as young as 28 to 32 days of age, in which 80% to 100% of feathers may be affected within a week of infection. A non-regenerative anaemia can be present, with a packed cell volume (PCV) of 14%

to 25%. Asymmetric, slowly progressing dystrophy of growing feathers, which gets worse with each subsequent moult, is a hallmark of chronic Pbfd. Those birds that survive the acute stage usually then experience a prolonged incubation period that may last for many years before any clinical symptoms reappears. Retained feather sheaths, pulp haemorrhage, curled feathers, and circumferential feather shaft constriction are all symptoms of feather dystrophy. Usually, the down and contour feathers are affected first, whereas the primary feathers are affected later. Birds can also develop complete alopecia and at times, beak abnormalities manifested as progressive elongation of beak and necrosis of palate rostrally can also occur. These birds

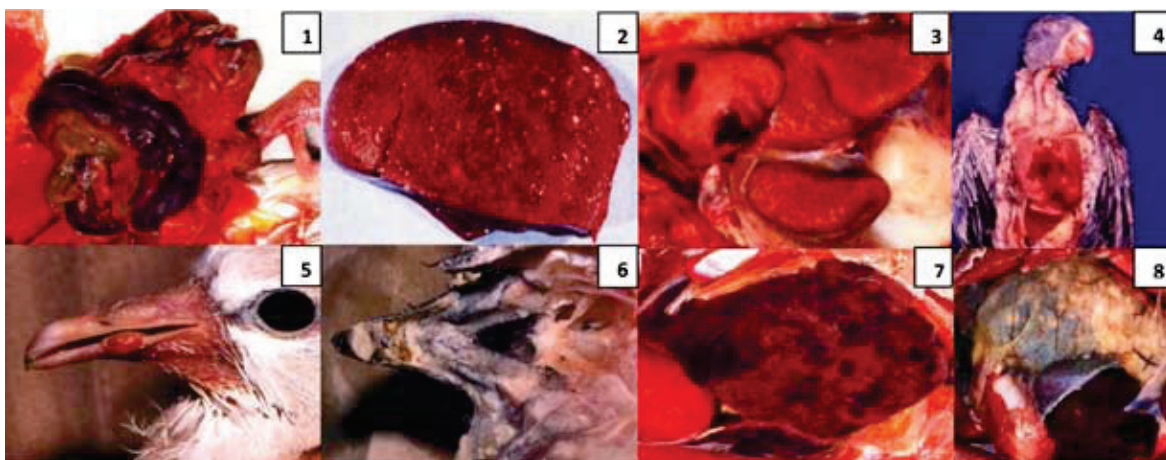


Fig.1: Marked intestinal haemorrhage in herpesvirus infection. **Fig.2:** Severely necrotic liver in pacheco's herpes viral infection. **Fig.3:** Epicardial haemorrhages with severely necrotic liver in polyoma viral infection. **Fig.4:** Polyoma virus induced severe skeletal muscle haemorrhages. **Fig.5:** Poxvirus induced nodule formation in beak. **Fig.6:** Necrosis of beak in circovirus infection. **Fig.7:** Appearance of swollen and mottled liver in adenoviral infection. **Fig.8:** Dilated proventriculus completely occupying the abdomen in proventricular dilatation disease.

Courtesy to: Schmidt, R.E., Struthers, J.D. and Phalen, D.N. eds., 2024. *Pathology of pet and aviary birds*. John Wiley & Sons.

often die of secondary bacterial or fungal infections due to immunosuppression. Intracytoplasmic inclusion bodies are observed in the thymus, bursa and bone marrow of affected birds.

A Pbfd variant, *Psittacine circovirus-2* (PsCV-2) has been described in lorries. The pathogenicity of PsCV-2 is found to be lesser than the originally described Pbfd. Lorries that had PsCV-2 had clinical feather lesions that were similar to Pbfd, but they had less severe clinical signs and most importantly, they recovered. Clinically affected birds exhibited lethargy, anorexia, diarrhoea, and inadequate weight gain. Squabs that are 7 to 8 weeks old have the highest death rates. Spleen, gut associated lymphatic tissues and the cloacal bursa manifest intracytoplasmic inclusion bodies (Smyth *et al.*, 2001; Roy *et al.*, 2003). Host switching of Psittacine circovirus to Finches (*Fringilidae*) are also reported. A recent finding from Sarker *et al.* (2015) revealed chance of psittacine circoviral infection in Rainbow bee-eater (*Merops ornatus*) and Powerful owl (*Ninox strenua*), which indicates the possibilities of cross species or host switching abilities of *Circoviridae* family of viruses.

Herpesviridae

Herpesviruses are DNA viruses with an envelope that are typically host-specific.

They cause lifelong latent infections with intermittent shedding and mild disease in adapted hosts and severe diseases in non-adapted hosts. The Pacheco's disease virus, Amazon tracheitis virus, Pigeon herpesvirus and other avian herpesviruses causing infections in pet birds have all been identified. The Pacheco's disease virus (PDV) has about three unique serotypes that can be found worldwide. Pigeons may get infected with some psittacine strains. PDV can cause clinical disease in all psittacine birds. Affected birds are frequently found with no premonitory symptoms. They occasionally display neurologic symptoms, anorexia, diarrhoea, and biliverdinuria. Mortality approaches to about 80%. PDV is clearly indicated by the appearance of hepatic intranuclear inclusion bodies (Cowdry type A bodies). The histologic lesions range from the severe haemorrhagic or fibrinonecrotic inflammation that primarily affects the upper respiratory tract to a proliferative bronchitis with mild necrosis and syncytial cell formation. Type A nuclear inclusion bodies can be found in bronchial epithelial and syncytial cells. The defining lesions of Pacheco's virus (PsHV-1) are massive hepatic and splenic necrosis with syncytial cells and eosinophilic intranuclear inclusion bodies. Occasionally, intranuclear inclusions and necrotic lesions have been described in a variety of other tissues. Outside of the liver

and the spleen, the pancreas, crop, and intestine are most likely to contain lesions. Less commonly, kidney, endocrine organs or cloaca are also involved. It is unusual for Pacheco's disease to affect the respiratory system, but when it does, the intranuclear inclusions have been observed in epithelial and syncytial cells of the larynx, trachea, and bronchi.

Amazon tracheitis virus (ATV) can cause infectious laryngotracheitis in gallinaceous birds. There are three different presentations: per acute, acute and chronic. In the per acute form, severe diphtheritic lesions can be observed in the trachea and bronchial tubes. Tracheal necrosis is the common finding in acute form. Conjunctivitis, sinusitis, coughing, rales, and secondary bacterial respiratory infections are all symptoms of the chronic type. Histologically, it is possible to see tracheal necrosis and bleeding, as well as pharyngitis, ingluvitis and air sacculitis.

Parakeet herpesvirus is believed to be distinct from ILT because intranuclear inclusion bodies are observed in lungs, rather than in trachea. As per the report by Ritchie (1995), the parakeet herpesvirus causes severe respiratory disease that affect the lungs and air sacs and also lead to neurologic manifestations resulting in fatalities.

Finch cytomegalovirus was previously classified as a host specific beta herpesvirus. Genetic sequencing results are now clustering this as an alpha herpesvirus within the genus *Illtovirus*. It appears to be a disease affecting primarily finches, especially Gouldian finches and it is characterized by conjunctivitis, rhinitis, pharyngitis, tracheitis, and bronchitis leading to heavy mortality. The prominent gross lesion is a hyperemic and oedematous conjunctiva. The air sacs may be thickened with fibrin. The conjunctivae, syrinx, and bronchi will all have a hyperplastic epithelium with cytomegaly (exceeding 40 µm in diameter) and karyomegaly. The oesophagus and nasal conchae have focal diphtheritic lesions with the characteristic inclusion bodies. The viral inclusions are large intranuclear basophilic inclusion bodies within cytomegalic cells.

The Amazon tracheitis virus, parakeetherpesvirus and other herpesviruses are found to cause pneumonia. The gross pulmonary lesions are oedema and congestion. Within the lung, intranuclear inclusions are observed in epithelial and syncytial cells of the parabronchi. Similar inclusions and syncytial cells may also be present in the tracheal epithelium and air sacs. Amazon tracheitis virus is generally associated with severe haemorrhagic or fibrino-necrotic inflammation that primarily

affects the upper respiratory tract as well as the lung. Parakeet herpesvirus results in a proliferative bronchitis with mild necrosis and syncytial cell formation (Schmidt *et al.*, 2015). Wartlike gastrointestinal papillomatosis has been associated with *Psittacid herpesvirus-1* (PsHV-1). Infections with PsHV-1 are most frequently seen in the Amazon parrots and macaws. These birds are susceptible to concurrent bile duct or GI tract carcinoma, which was recently found in association with PsHV-1, genotype 3. PsHV-1 associated liver or GI carcinoma has also been reported in an African grey parrot, Eclectus parrot and a Cockatiel (Trapp *et al.*, 2008).

Papillomaviridae

Papillomavirus causes true warts in birds. They are highly host specific and are found to cause benign skin masses on the face and head of African grey parrots and the legs and feet of passerine birds. These masses are characterized histologically by long, thin folds of hyperkeratotic epidermis that is accompanied by acanthotic parakeratosis (Ritchie, 1995). They can also cause cutaneous lesions in European finches, canaries, and the African grey parrot. Lesions in finches are found on the feet and lesions in canaries are found at the corner of the beak, and the lesions on African grey parrots are widely disseminated on the face. Grossly this disease is characterized by

the presence of multiple proliferative skin lesions that superficially resemble those caused by mite infestations and poxvirus infections (Ritchie, 1995). Histologically, the lesions are of hyperplastic epithelial cells supported by a vascular stroma. Epidermal nuclei are often enlarged and homogeneous, suggestive of inclusion body formation. Well-defined inclusion bodies usually are not seen, but viral particles are demonstrated by electron microscopy. Similar lesions are seen in cockatiels but have not been characterized.

Polyomaviridae

In mammals, polyomaviruses induce subclinical disease; however, in psittacine and other birds, they cause severe clinical disease. The first polyomavirus described was in budgerigars in 1981. The disease, known as budgerigar fledgling disease, affects budgerigars differently than it does other psittacine birds. Budgerigars show evidence of poor feather development, particularly in contour feathers, abdominal distension, subcutaneous haemorrhage, and young birds die suddenly with or without neurologic symptoms like ataxia and tremors.

Psittacine birds typically develop subclinical disease because their developed, healthy immune systems protect them from the disease's acute form. For the rest of their

lives, these birds intermittently excrete polyomavirus. The disease can manifest in immature non budgerigar psittacine birds in acute, subacute, or chronic forms, depending mostly on age of initial exposure. Per acute form causes death in young birds. Young birds can also get acute disease, which has a mortality rate of about 27% to 41% and can cause symptoms like depression, anorexia, delayed crop emptying, regurgitation, diarrhoea, dehydration, subcutaneous haemorrhage, dyspnoea, and polyuria which can last for a period of 12 to 48 hours. Subcutaneous haemorrhages are most noticeable in the crop or skull. Weight loss, sporadic anorexia, polyuria, renal failure, poor feather growth, and immunosuppressive symptoms such as secondary bacterial or fungal infections, collectively characterize chronic disease. Birds afflicted with immunosuppressive conditions exhibit a compromised ability to combat the infection, consequently predisposing them to the emergence of chronic form (Kingston *et al.*, 1992).

Polyomavirus is seen in a variety of psittacine birds and can also cause heart disease in finches. Gross lesions include haemorrhage, cardiomegaly, and hydropericardium. Patchy pale regions are also observed in the myocardium. Histologically, there is haemorrhage, variable non-suppurative inflammation,

and coagulative necrosis of myofiber. Myocyte nuclei may have karyomegaly, with chromatin margination and inclusion body development.

Typically, polyomavirus inclusions are granular and basophilic, pale or nearly transparent, or both. Viral intranuclear inclusion bodies can be detected in feather follicles and renal tissue. Gross and histologic lesions in non-budgerigar psittacine differ slightly from those in budgerigars. In this illness, haemorrhage is much more noticeable and can be observed in subcutaneous tissues and serosal surfaces. Petechial and ecchymotic haemorrhages on the epicardial surface is also frequently noted. Birds lose so much blood that they become exceedingly pale, and their muscles take on an odd orange colour. If there is inflammation, it is mainly lymphoplasmacytic in nature. Necrosis, inflammation, and inclusion bodies have all been observed in finches (Schmidt *et al.*, 2015).

In the classic cases of avian polyomavirus (APV), there are either no histologic changes in the lungs or the interstitium of the lung is expanded with mononuclear inflammatory infiltrates. Rarely large pale basophilic intranuclear viral inclusions can be identified within this mononuclear population. Those birds with chronic illness often appear emaciated.

Grossly their lungs are moist and may have a decreased buoyancy. Histologically there is a diffuse interstitial pneumonia. There appears to be a proliferation of type II pneumocytes, and there is severe pulmonary oedema and numerous viral inclusions (Fitzgerald *et al.*, 1995). There have been a few reports of polyomavirus infection of the beak germinal epithelium. Inflammation and necrosis were noted, as well as intranuclear inclusion bodies. Narrowing and elongation of the beak of finches, particularly Gouldian finches, is ascribed to infection with finch polyomavirus. Birds with APV disease typically have an enlarged and often haemorrhagic spleen. Histologically there is multifocal splenic necrosis. Karyomegaly with typical lightly basophilic to clear intranuclear inclusions are usually prominent and may be massive, particularly in macrophages of the splenic periarteriolar sheaths. Impression smears of the affected spleen may contain numerous inclusions. Karyomegaly can also be prominent in splenic reticular cells. A nonspecific lymphocytic depletion may also occur. Recovery from APV disease is rare and the surviving birds are left with little functional tissues in their spleen. (Roy *et al.*, 2004).

In some outbreaks in budgerigars, significant cerebellar lesions may also be seen. Affected chicks will have

prominent intention tremors. Characteristic intranuclear inclusion bodies with karyomegaly are abundant in the molecular layer of the cerebellum. Lesions in these birds are often confined to the grey matter of the brain. This includes haemorrhage and degeneration of astrocytes and neurons with characteristic intranuclear inclusions found in some of these cells. Inflammation was not seen in these birds. The second case was concurrently infected with the psittacine beak and feather disease virus, suggesting that immunosuppression may play a role in this disease (Manarolla *et al.*, 2007)

Polyomavirus in integumentary system

Polyomavirus was originally reported as a disease of budgerigars, with feather loss as one of the primary clinical signs. Feather dysplasia is a common finding in fledgling budgerigars raised in large commercial aviaries. Grossly, primary wing feathers and tail feathers are either absent entirely or they have thick sheaths, and there may be haemorrhage in their shafts. These birds may be typically infected with avian polyomavirus, psittacine beak and feather disease virus (PBFDV) or both. Feather disease may be the only manifestation of avian polyomavirus. In budgerigars, a systemic form of the disease is seen in nestlings. Affected nestlings usually exhibit dysplasia of contour feathers, down

feathers, flight feathers, or a combination of all of them. Within the growing feather, there is often massive infection of the cells in the zone of differentiation, with nearly every cell showing karyomegaly and containing the characteristic intranuclear inclusion bodies. Inclusions can also be seen in the epidermis of the skin. But such findings are often uncommon. Feather changes are also rare in larger psittacine birds with avian polyomavirus. However, in some cases these birds will have haemorrhage within the shaft of affected feathers. In non-budgerigar parrots affected with avian polyomavirus disease skin and subcutaneous haemorrhages are a common finding. Non-psittacine birds with polyomavirus infection rarely have gross feather changes.

Polyomavirus infection in passerine birds can lead to acute death. Those that survive may experience beak malformation and feather deterioration. Gross necropsy findings include sub-serosal intestinal bleeding, splenomegaly with congestion and hepatomegaly with paleness and mottling. Intranuclear inclusion bodies can be observed in the intestine, spleen, liver, heart and kidney. APV disease is rare in lovebirds, but the disease has been reported in nestlings. Hepatic necrosis is a common finding in these birds, but inclusion bodies are commonly found in other organs as well.

Fledgling and young adult lovebirds are also susceptible to APV disease. This may also be a manifestation of immunosuppression from a concurrent PBFDV as this disease is extremely common in this species.

Paramyxoviridae

Generally, psittacine birds and pigeons are considered more resistant to Paramyxoviral infections. But free ranging pigeons can serve as mechanical vectors. Infected passerine birds with Paramyxovirus-2 (PMV-2) shows moderate, self-limiting disease, but infected psittacine birds particularly African grey parrots, exhibit severe respiratory difficulties, diarrhoea with significant fatality rates. PMV-3 has been isolated from a large variety of both clinically normal and dead psittacine and passerine birds. In *Neophema* spp., the morbidity is high and the mortality is low. Clinical signs include torticollis and ataxia. Gross necropsy findings include pulmonary edema and congestion, hepatomegaly, and pancreatic atrophy. Nestling cockatiels exhibits high mortality after manifestation of clinical signs - opisthotonus, leg paralysis, and dyspnoea. Grossly, cardiomegaly and pericardial effusion are also reported. In Japan, PMV-5 was found in budgerigars with significant clinical symptoms such as depression, diarrhoea, torticollis, dyspnea, and high (90%) mortality. Young birds

seem to be more susceptible to the infection than adults.

Poxviridae

Poxviruses are the largest of viruses and the genus *Avi* poxviruses are found worldwide in greater than 20 families of birds. There are many species of *avi* poxvirus, such as psittacine pox, canary pox, pigeon pox, falcon pox and fowl pox. *Avi* poxviruses are epitheliotropic viruses that have cutaneous, mucosal (diphtheritic), and systemic presentations and in some outbreaks all three forms can be identified. Canary poxvirus, a virulent avipoxvirus, generally presents as a systemic infection and can cause up to 100% mortality in susceptible canary (*Serinus canaria*) flocks as well as other passerines such as finches and sparrows. Secondary infections with bacteria and/or fungus can significantly contribute to the mortality. Upper respiratory tract disease, pneumonia, air sacculitis, and splenomegaly are usually evident. A common early lesion is of a periocular proliferative dermatitis and the most significant lesion is the proliferative bronchopneumonia. Each species of pox has varied host specificity, but typically the most severe clinical signs are seen in its natural host. Wet pox consists of mucosal papular lesions of the oropharynx which can be distinguished from dry pox, it consists of cutaneous papular lesions.

Occasionally, birds may display neurologic signs. In psittacine pox, corneal ulcers or crystallization may occur with or without uveitis, that can later lead to scarring. Wet or mucosal form of pox can cause pneumonia or air sacculitis. Agapornis pox, which affects lovebirds specifically, has a morbidity and mortality rate of about 75%. Lovebirds develop areas of dry, darkened skin, but not papules. Canary pox can lead to the formation of lung tumours.

Histologically, pox is characterized by marked epithelial hyperplasia and vacuolar degeneration of airway epithelial cells associated with small numbers of mixed inflammatory cells. The lesions are progressive, starting in the nasal cavity as a proliferative rhinitis, continuing through the trachea, and finally reaching the lungs and airsacs. Scattered areas of coagulative necrosis may be present within the mucosa. The virus forms eosinophilic intracytoplasmic inclusion bodies called ‘bollinger bodies’ and borrel granules. In birds surviving the initial clinical manifestations, cutaneous lesions may subsequently develop. Systemic pox viral infection can lead to multifocal necrosis and variable inflammation in air sacs. It can also cause necrotizing pharyngitis characterised by multifocal to confluent raised yellow foci. Histologically, there is ballooning degeneration of epithelial cells

with intracytoplasmic inclusions. Variable necrosis and inflammation are present and there may be evidence of secondary infections. Poxviruses can also affect the beak. Beak lesions are most commonly found in non-psittacine birds but are also occasionally seen in psittacine birds. Classically, poxvirus infection causes raised proliferative lesions that may or may not be necrotic and secondarily infected. These lesions are seen on the beak or at the beak-skin margin. Occasionally there may be infection of the basal layers of the beak epidermis, with sloughing of the keratinized layers leading to the gross presentation of a beak with no keratinized structure.

Reoviridae

Three genera - *Orthoreovirus*, *Orbivirus*, and *Rotavirus* that make up the *Reoviridae* family have all been identified in pet birds. Among them, the most studied are the Orthoreoviruses. They cause tenosynovitis in chicken. Birds infected with reoviruses exhibit a range of clinical symptoms which may be unclear and exacerbated by coexisting fungal or bacterial infections. In case of psittacine birds, the liver is the main target organ wherein it is possible to see intracytoplasmic inclusion bodies. The virus has also been found in the pancreas, spleen, bursa, and even in circulating cells (Sanchez-Cordon *et al.*, 2002).

Proventricular dilatation disease

The causative agent of the disease has been remarked as an unidentified 89-nm virus. The agent infects birds of many orders, including psittacine species. They gain entry into the body of the host through oral to faeces route of transmission. Severe, prolonged weight loss, regurgitation, delayed crop emptying, insatiable hunger, undigested food in stool, and neurological symptoms are the clinical manifestations. The virus paralyzes the nerves in the proventriculus, and the bird essentially starves to death because of its inability to process food. Other nerves or organs can also be affected in conjunction with the proventriculus. Suggestive diagnostic testing includes radiographs that demonstrate proventricular dilatation and whole, undigested food particles or seeds in the faeces. Apart from viruses other agents causing proventricular dilation, includes parasites, yeast, megabacterium, mycobacterium, foreign body, neoplasia, lead and zinc toxicosis.

For viral proventricular dilatation disease, the definitive diagnostic testing includes crop biopsy that demonstrates a “lymphoplasmocytic ganglioneuritis.” Electron microscope that demonstrates 89-nm virus in the faeces is highly suggestive, but the virus is labile and does not withstand overnight shipping. Birds usually die

within 2 years of developing clinical signs. Heart lesions are relatively common in the vast range of psittacine and non-psittacine birds that are infected with the avian bornavirus and develop proventricular dilatation disease (Kistler *et al.*, 2008). On a gross level, the ventricles may appear to be slightly dilated, and sporadic pale foci and streaks are visible. Histologically, nerve ganglia, the epicardium, and heart exhibits multifocal lymphoplasmacytic and histiocytic infiltrates, especially close to cardiac conduction fibres. When these lesions are severe, the conduction system may be affected, which could result in immediate death. There is a chance for myocyte necrosis and, less frequently, fibrosis. Overall myocarditis is a prominent finding in borna virus infection.

Togaviridae

It is believed that the condition known as avian viral serositis is caused by virions belonging to the family *Togaviridae*, a causative of eastern equine encephalomyelitis. This condition causes heart lesions such as epicarditis and the heart appears fibrinous, grey, and yellow. Additionally, hazy pericardial fluid may be present in excess. Histiocytes, plasma cells, and lymphocytes can all be found inside histologic lesions (Schmidt *et al.*, 2015). Although inclusion bodies are not visible, viral nucleocapsids are observed ultrastructurally close to the cytoplasmic

and intracytoplasmic membrane. Gregory *et al.* (1997) isolated an eastern equine encephalomyelitis (EEE) virus in PDD case of psittacine birds which exhibits the same lesions.

CONCLUSION

Most of the viral infections affecting pet birds are multisystemic in nature. Among the various pathophysiology, immunosuppression is a major concern that can lead to secondary bacterial infections resulting in serious illness and eventually death. According to the recent findings, host-switching and cross species infections also serve as major threats in viral infections of pet birds. Differentials in proventricular dilatation disease of pet birds suggests that there is a multispecies aetiology which is still under investigation. Many viruses have been implicated to cause disease in pet birds, but certain families of viruses that have been discovered in mammals have not been associated with disease in birds. It is imperative to perform a necropsy on any birds that die whether a pet, aviary, or display bird to arrive at a proper diagnosis because co-infections with multiple infectious agents can complicate diagnosis and treatment, especially in cases of immunosuppression. Also, it is imperative to use available vaccines to decrease and control the incidence of these diseases, as has occurred in the canine and feline pet populations.

REFERENCES

- Fitzgerald, S.D., Reed, W.M. and Fulton, R.M. 1995. Development and application of an immunohistochemical staining technique to detect avian polyoma viral antigen in tissue sections. *J. Vet. Diagn. Invest.* **7**: 444-450.
- Goodwin, M.A. 1992. Adenovirus particles and inclusion body hepatitis in pigeons. *J. Assoc. Avian Vet.* **6**: 37-39.
- Greenacre, C.B. 2005. Viral diseases of companion birds. *Vet. Clin. N. Am. - Exot. Anim. Pract.* **8**: 85-105.
- Greenacre, C.B., Latimer, K.S., Niagro, F.D., Campagnoli, R.P., Pesti, D. and Ritchie, B.W. 1992. Psittacine beak and feather disease in a scarlet macaw (*Ara macao*). *J. Avian Med. Surg.* 95-98.
- Hess, M. 2013. Aviadenovirus infections. *Diseases of Poultry*, 290-300.
- Kingston, R.S. 1992. Budgerigar fledgling disease (Papovavirus) in pet birds. *J. Vet. Diagn. Invest.* **4**: 455-458.
- Kistler, A.L., Gancz, A., Clubb, S., Skewes-Cox, P., Fischer, K., Sorber, K., Chiu, C.Y., Lublin, A., Mechani, S., Farnoushi, Y. and Greninger, A. 2008. Recovery of divergent avian bornaviruses from cases of proventricular dilatation disease: Identification of a candidate etiologic agent. *Virology* **5**: 1-15.
- Manarolla, G., Liandris, E., Pisoni, G., Moroni, P., Piccinini, R. and Rampin, T. 2007. Mycobacterium genavense and avian polyomavirus co-infection in a European goldfinch (*Carduelis carduelis*). *Avian Pathol.* **36**: 423-426.
- Rinder, M., Schmitz, A., Baas, N. and Korbel, R. 2020. Molecular identification of novel and genetically diverse adenoviruses in Passeriform birds. *Virus Genes.* **56**: 316-324.
- Ritchie, B.W. 1995. Avian viruses: function and control. Wingers Publishing Inc., Florida .
- Roy P, Dhillon AS, Lauerma L. 2003. Detection of pigeon circovirus by polymerase chain reaction. *Avian Dis.* **47**: 218-22.
- Roy, P., Dhillon, A.S., Lauerma, L. and Shivaprasad, H.L. 2004. Detection of avian polyomavirus infection by polymerase chain reaction using formalin-fixed, paraffin embedded tissues. *Avian Dis.* **48**: 400-404.
- Sanchez-Cordon, P.J., Hervas, J., De Lara, F.C., Jahn, J., Salguero, F.J. and Gomez Villamandos, J.C. 2002.

- Reovirus infection in psittacine birds (*Psittacus erithacus*): morphologic and immunohistochemical study. *Avian Dis.* **46**: 485-492.
- Sarker, S., Lloyd, C., Forwood, J. and Raidal, S.R. 2015. Forensic genetic evidence of beak and feather disease virus infection in a Powerful Owl, *Ninox strenua*. *Emu*, **116**: 71-74.
- Sarker, S., Moylan, K.G., Ghorashi, S.A., Forwood, J.K., Peters, A. and Raidal, S.R. 2015. Evidence of a deep viral host switch event with beak and feather disease virus infection in rainbow bee-eaters (*Merops ornatus*). *Sci. Rep.* **5**: 1-8.
- Schmidt, R.E., Reavill, D.R. and Phalen, D.N. 2015. Pathology of pet and aviary birds. John Wiley & Sons. 320.
- Schoemaker, N.J., Dorrestein, G.M., Latimer, K.S., Lumeij, J.T., Kik, M.J.L., Van Der Hage, M.H. and Campagnoli, R.P. 2000. Severe leukopenia and liver necrosis in young African grey parrots (*Psittacus erithacus erithacus*) infected with psittacine circovirus. *Avian Dis.* 470-478.
- Smyth, J.A., Weston, J., Moffett, D.A. and Todd, D. 2001. Detection of circovirus infection in pigeons by in situ hybridization using cloned DNA probes. *J. Vet. Diagn. Invest.* **13**: 475-482.
- Soike, D., Hess, M., Prusas, C. and Albrecht, K. 1998. Adenovirus infections in psittacines. *Tierarztl. Prax. Ausg. K Kleintiere Heimtiere.* **26**: 354-359.
- Trapp, S. and Osterrieder, N. 2008. Herpesviruses of birds. *Desk Encyclopedia of Microbiology.* 415.
- Vaz, F.F., Raso, T.F., Agius, J.E., Hunt, T., Leishman, A., Eden, J.S. and Phalen, D.N. 2020. Opportunistic sampling of wild native and invasive birds reveals a rich diversity of adenoviruses in Australia. *Virus Evol.* **6**: 024.
- Walker, D., Gregory, W.F., Turnbull, D., Rocchi, M., Meredith, A.L., Philbey, A.W. and Sharp, C.P. 2017. Novel adenoviruses detected in British mustelids, including a unique Aviadenovirus in the tissues of pine martens (*Martes martes*). *J. Med. Microbiol.* **66**: 1177.
- Woods, L.W., Latimer, K.S., Niagro, F.D., Riddell, C., Crowley, A.M., Anderson, M.L., Daft, B.M., Moore, J.D., Campagnoli, R.P. and Nordhausen, R.W. 1994. A retrospective study of circovirus infection in pigeons: nine cases (1986–1993). *J. Vet. Diagn. Invest.* **6**: 156-164.